

# Sinus vs Tooth

## Evaluation and treatment of odontogenic sinusitis

Jeff Adams, MD  
The Everett Clinic  
Department of Otolaryngology Head and Neck Surgery

# Topics tonight...

- **Sinusitis overview**
- **Treatment basics**
- **Odontogenic sinusitis**
- **Review of films and cases**
- **Endoscopic sinus surgery**

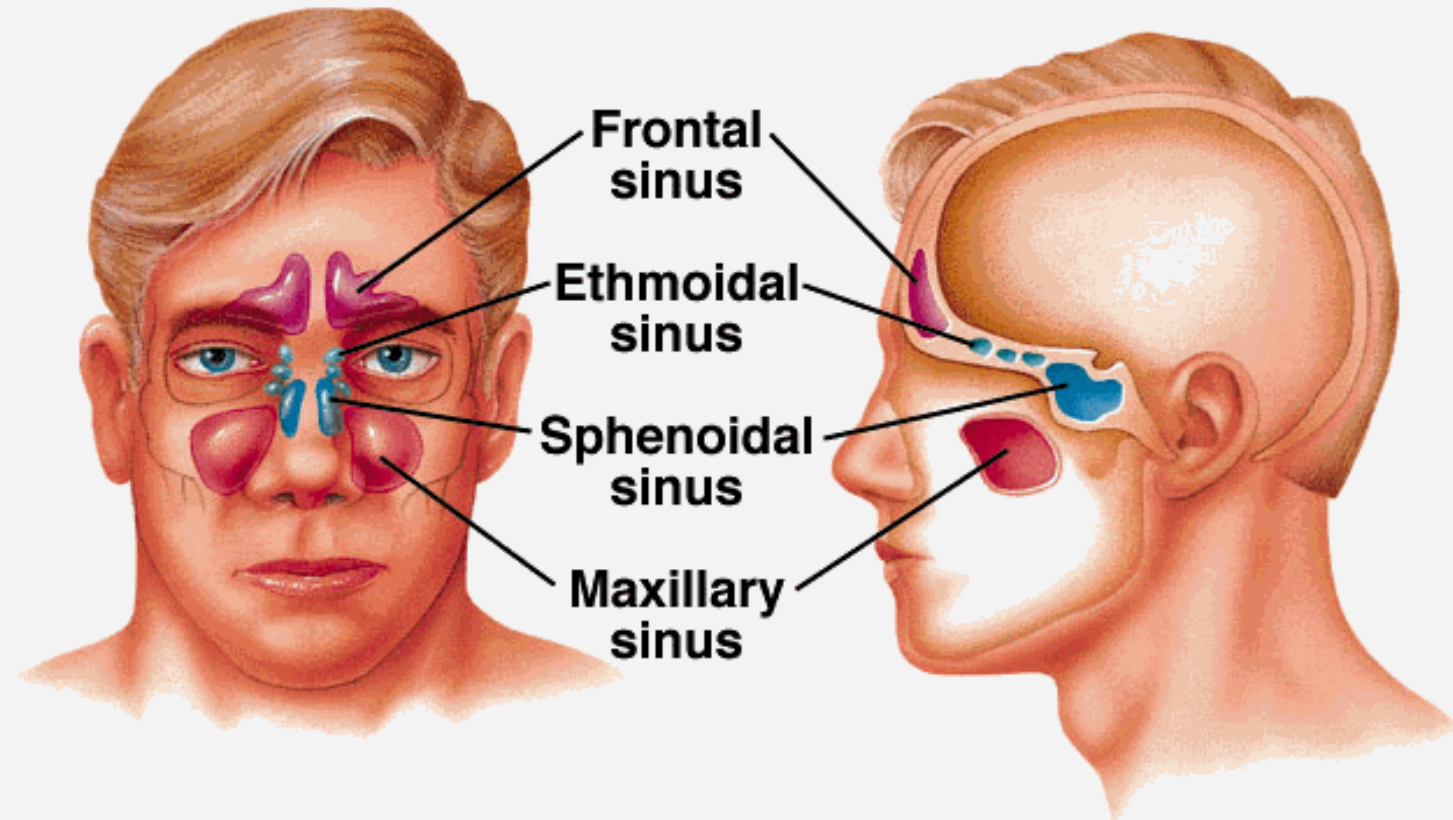
# Sinusitis

- Infection involving one or more of the four paranasal sinus areas
- 1 in 7 people in US each year (evaluated/treated)
- Presents across disciplines – ENT, Dental, Allergy, Neurology, PCP, WIC/ED, Pulmonary, Ophthalmology

# Anatomy

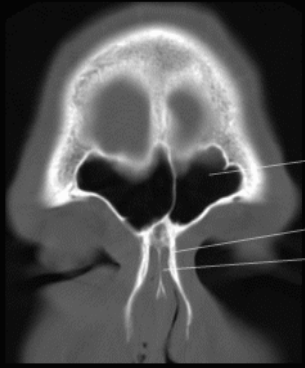
Copyright © The McGraw-Hill Companies, Inc. Permission required for reproduction or display.

## Sinuses

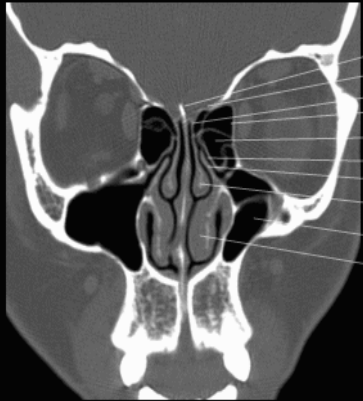


# Coronal CT

## Paranasal Sinuses

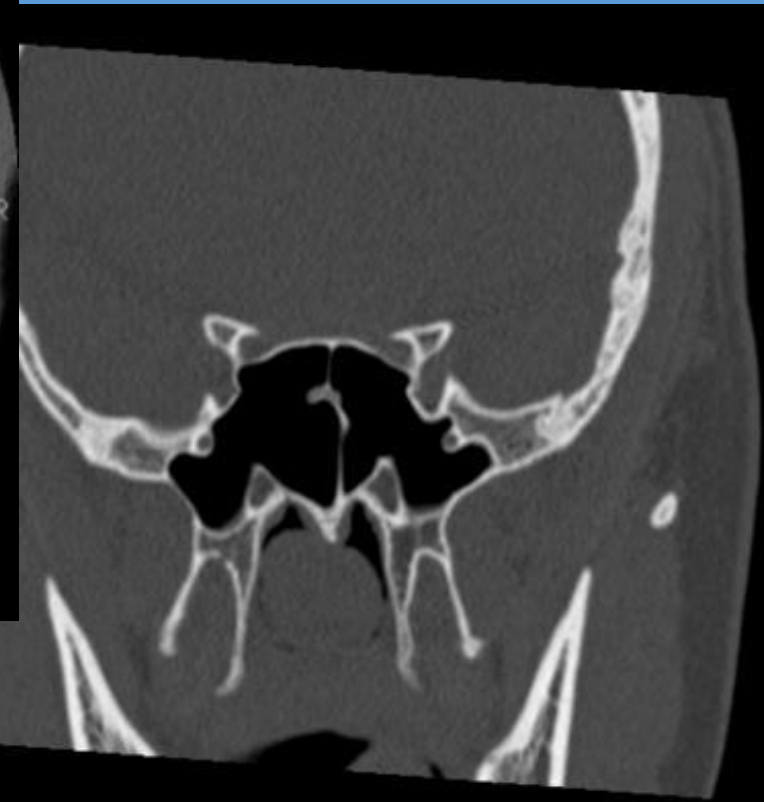
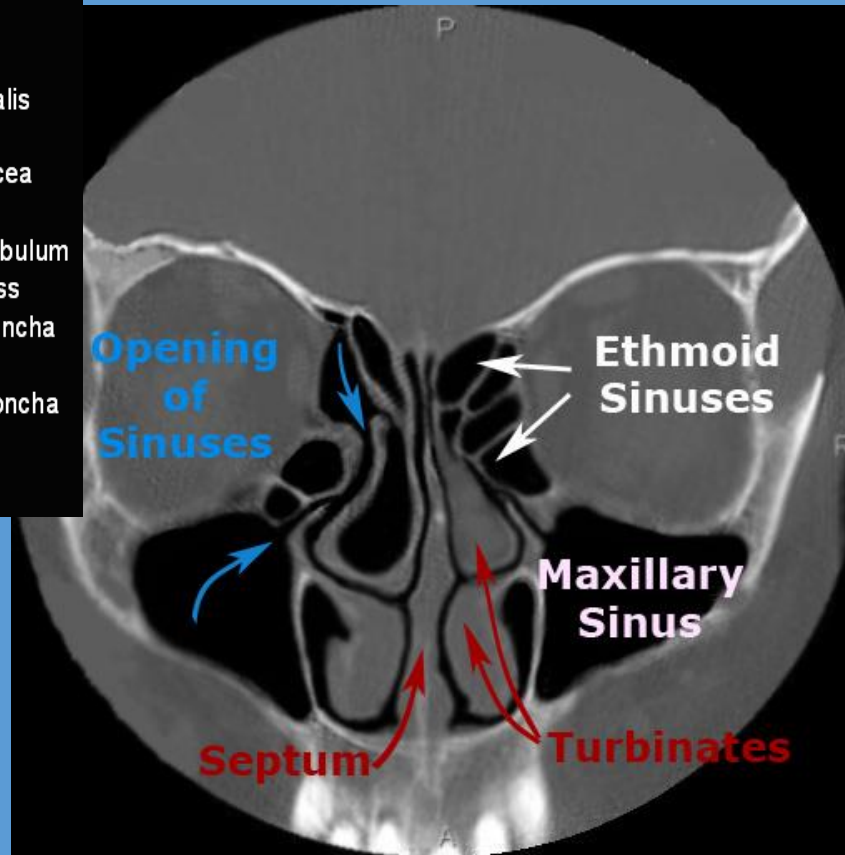


- Frontal sinus
- Nasal bone
- Perpendicular plate

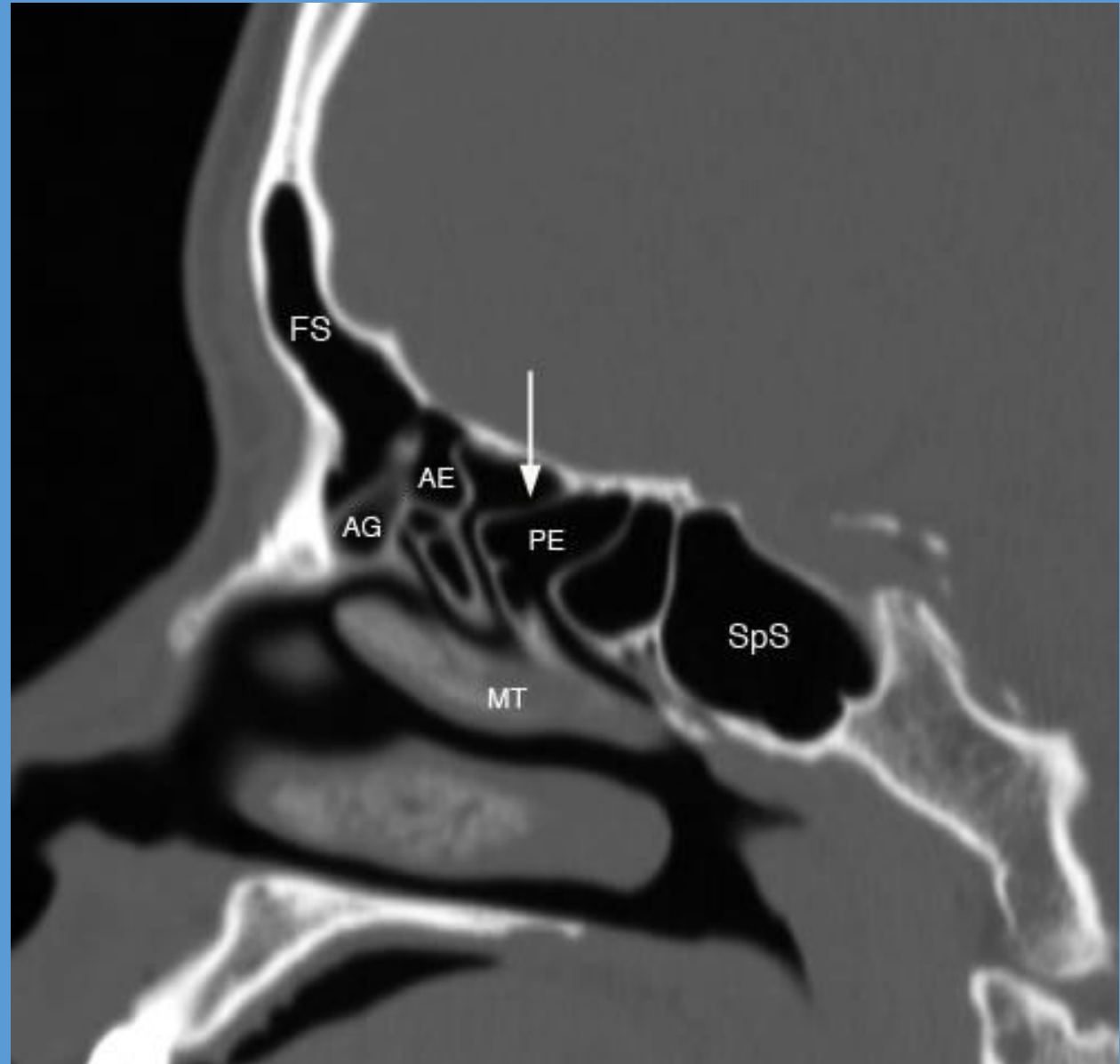


- Crista galli
- Fovea ethmoidalis
- Cribriform plate
- Lamina papyracea
- Ethmoid sinus
- Ethmoid infundibulum
- Uncinate process
- Middle nasal concha
- Maxillary sinus
- Inferior nasal concha

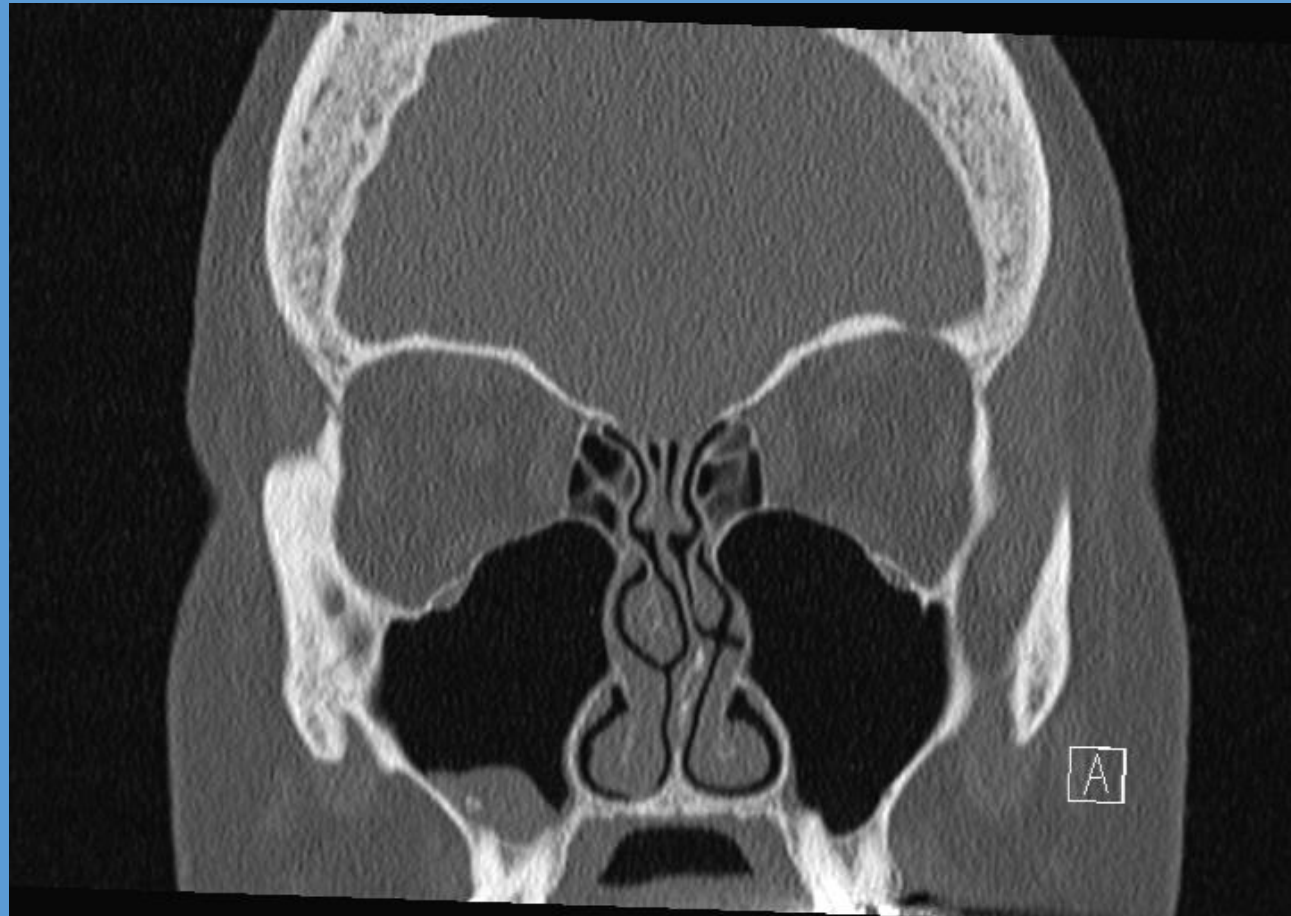
Coronal CT Scan



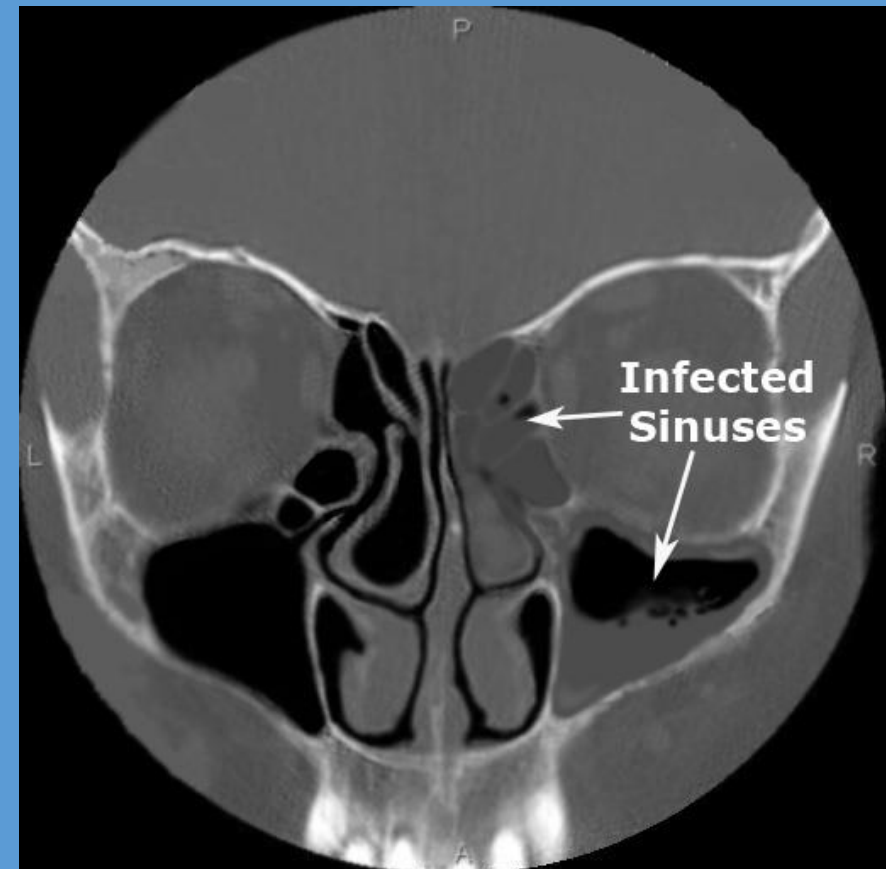
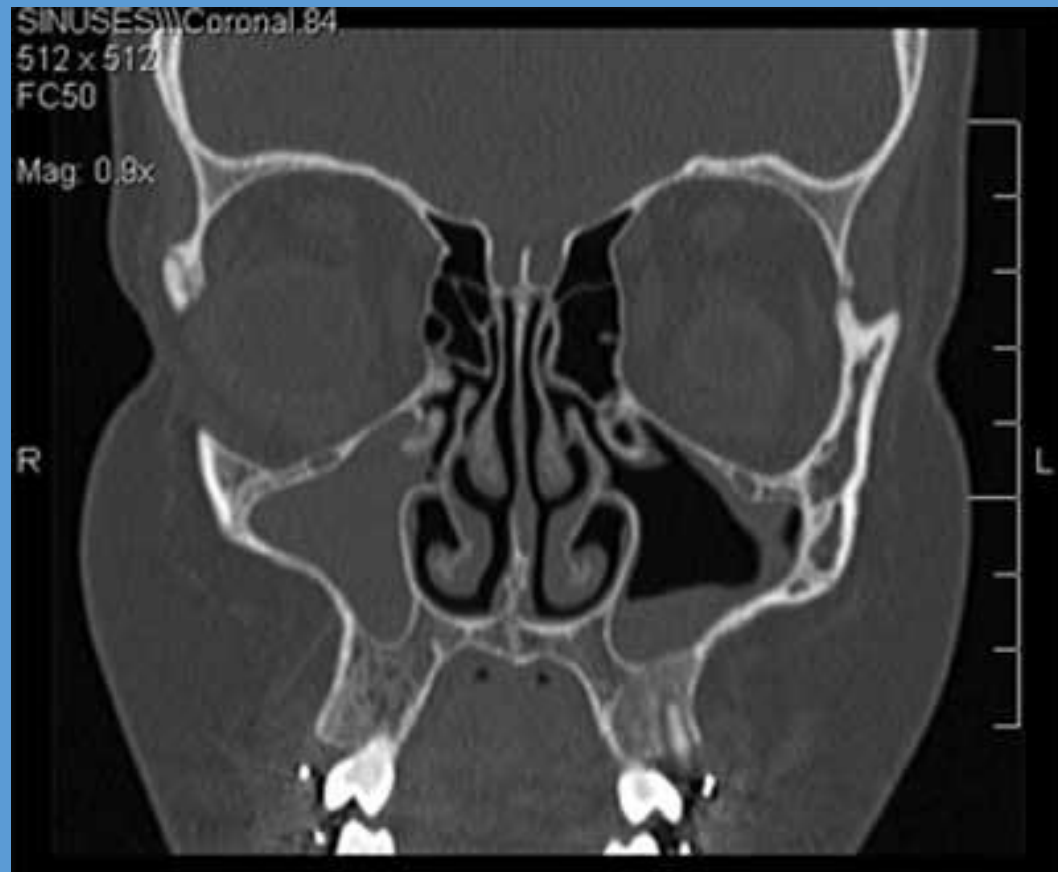
# Saggital CT



# Maxillary sinuses



# Sinusitis





# Sinusitis Treatment

## 1. Short course antibiotics (7-10 days), saline rinses, decongestants

- amoxicillin, azithromycin, cefazolin
- pseudoephedrine (behind the counter)
- oxymetazoline

Allergy?  
Neurology?



## 2. Long course antibiotics (2-4 weeks), nasal steroid sprays (30-90 days), oral steroids, saline rinses

- amox/clav, cefdinir, clarithromycin, levofloxacin



## 3. Surgery – for recalcitrant, repeated, and/or severe sinusitis

- Lasting more than a month, 4-6 episodes per year

# Sinusitis Treatment

## 1. Short course antibiotics (7-10 days), saline rinses, decongestants

- amoxicillin, azithromycin, cefazolin
- pseudoephedrine (behind the counter)
- oxymetazoline spray

Allergy?  
Neurology?



Dental finding....?

## 2. Long course antibiotics (2-4 weeks), nasal steroid sprays (30-90 days), oral steroids, saline rinses

- amox/clav, cefdinir, clarithromycin, levofloxacin, fluticasone, prednisone



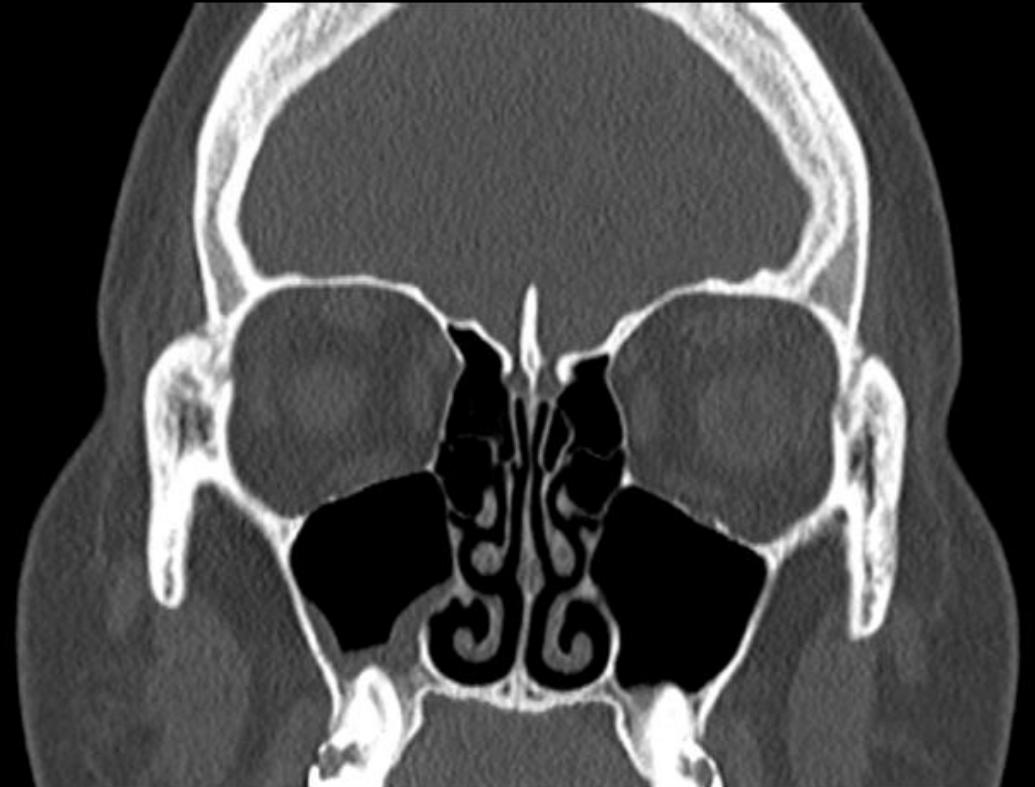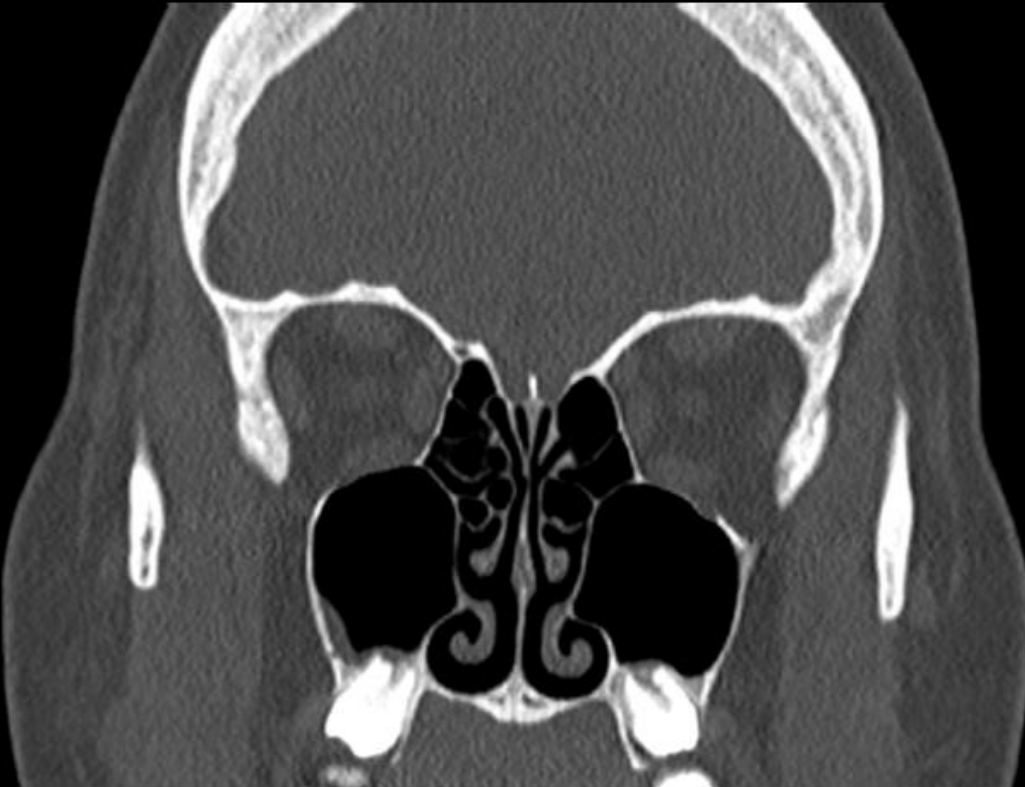Dental finding....?

## 3. Surgery – for recalcitrant, repeated, and/or severe sinusitis

- Lasting more than a month, 4-6 episodes per year

**21 y.o. male self referred for evaluation of chronic sinusitis.  
Sinus problems/symptoms for the past 2-3 months.**

**Baseline daily symptoms include congestion, nasal drainage, sinus pain and pressure, headaches and upper tooth pain.**



## Is dental evaluation considered in unilateral maxillary sinusitis? A retrospective case series.

**OBJECTIVE:** Are patients with symptomatic unilateral maxillary sinusitis sent for a dental evaluation of odontogenic maxillary sinusitis (OMS)?

**PATIENTS AND METHODS:** The medical records of all patients diagnosed with sinusitis at a university Ear-nose and throat (ENT) clinic from 2010 to 2015 were scrutinized for symptomatic unilateral maxillary sinusitis verified on CT. Any dental evaluation was recorded, as well as symptoms of OMS, duration to dental evaluation, diagnosis of OMS and dental treatment.

**RESULTS:** A total of 1338 patients diagnosed with sinusitis were screened; 172 had unilateral maxillary sinusitis and 48% (82/172) OMS. 34% did not have any dental evaluation at all. Patients referred to local specialist dental care waited a median of 11 weeks for evaluation and a median of 15 weeks further for dental treatment. **Symptoms more frequently reported in OMS patients were foul smell or taste** (43.9% vs 11.1%,  $p < .0001$ ), purulent rhinorrhea (40% vs 19.1%,  $p = .015$ ) than non-OMS patients. The OMS group also reported more frequently that they were active smokers (31.7% vs 10%,  $p = .0005$ ).

**CONCLUSIONS:** **OMS was found in 48% of unilateral maxillary sinusitis** and one-third of the patients with unilateral maxillary sinusitis had no dental evaluation. Low awareness of OMS could delay diagnosis and treatment.

## When Maxillary Sinusitis Does Not Heal: Findings on CBCT Scans of the Sinuses With a Particular Focus on the Occurrence of Odontogenic Causes of Maxillary Sinusitis.

**Objectives:** This study sought to investigate the **proportion of patients with suspected sinusitis referred for radiological examination who have radiologically verified sinusitis of odontogenic origin** and to describe this type of sinusitis.

**Study Design:** This investigation is a retrospective study.

**Methods:** A total of 303 sinus examinations involving cone beam computed tomography (CBCT) performed at Sunderby Hospital, Luleå, Sweden in 2012 were independently reviewed by two radiologists. The number of cases of maxillary sinusitis and the correlation between maxillary sinusitis and odontogenic infections were determined.

**Results:** Overall, **24% of the verified cases of sinusitis were odontogenic. An odontogenic origin was identified in 40% of unilateral maxillary sinusitis cases but only 6% of bilateral maxillary sinusitis cases ( $p = 0.0015$ ).** Forty-nine out of 54 patients with periapical destruction had adjacent mucosal swelling in the maxillary sinus, but only 15 of these patients satisfied the criteria for sinusitis.

**Conclusion:** The present study **confirms the close relationship between odontogenic infections and unilateral maxillary sinusitis. Level of Evidence 4.**

## Odontogenic rhinosinusitis and sinonasal complications of dental disease or treatment: prospective validation of a classification and treatment protocol.

**PURPOSE:** Odontogenic sinusitis and **sinonasal complications of dental disease or treatment (SCDDT)** represent a heterogeneous group of conditions that often require multidisciplinary care. The present study aims to prospectively validate a classification and treatment protocol for SCDDT patients.

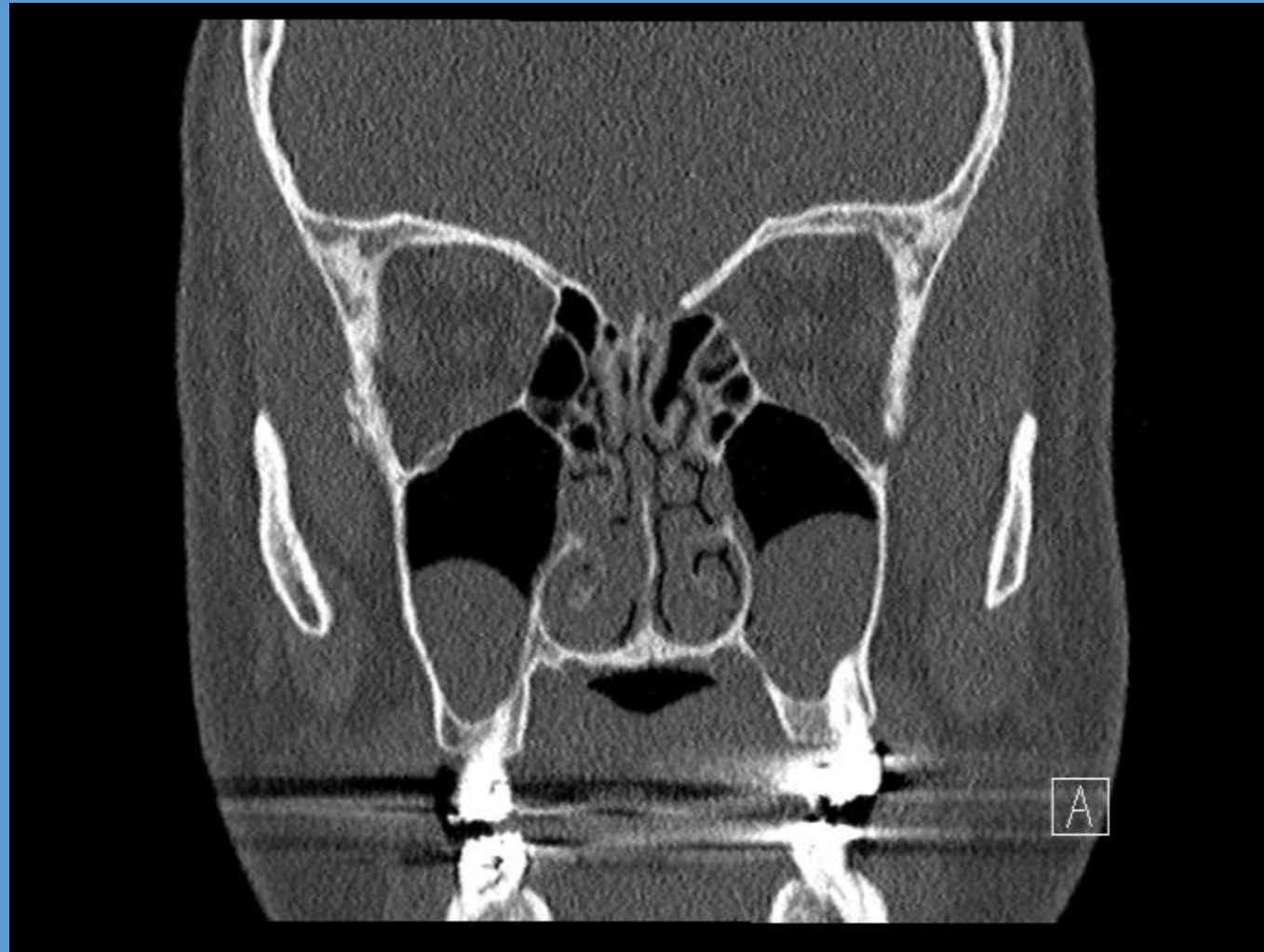**METHODS:** One hundred twenty-eight consecutive patients (73 females and 45 males, mean age 52.4 years) affected by SCDDT not responding to dental and medical therapy were classified and surgically treated according to the proposed protocol. The protocol **classified patients into three aetiology-based groups (preimplantologic, implantologic, and related to traditional dental diseases and procedures, respectively)**. The groups were further divided into classes according to the presence of oro-antral communications and/or dislocated dental hardware. Each condition was treated according to the class-related, protocol-defined treatment, by either a transnasal or combined transnasal/transoral approach. All patients were successfully classified according to our protocol. None of the proposed classes were redundant, and no condition fell outside the definitions.

**RESULTS:** The surgical treatment protocol proved to be adequate and effective, in that 125 of the 128 patients completely recovered after surgical treatment.

**CONCLUSIONS:** The term SCDDT and the consequent classification proposed by the authors appear, therefore, to be nosologically correct. Furthermore, the protocol-related proposed treatment appears to be clinically sound, with a success rate nearing 98%.

**35 y.o. male self referred for evaluation of sinusitis.**

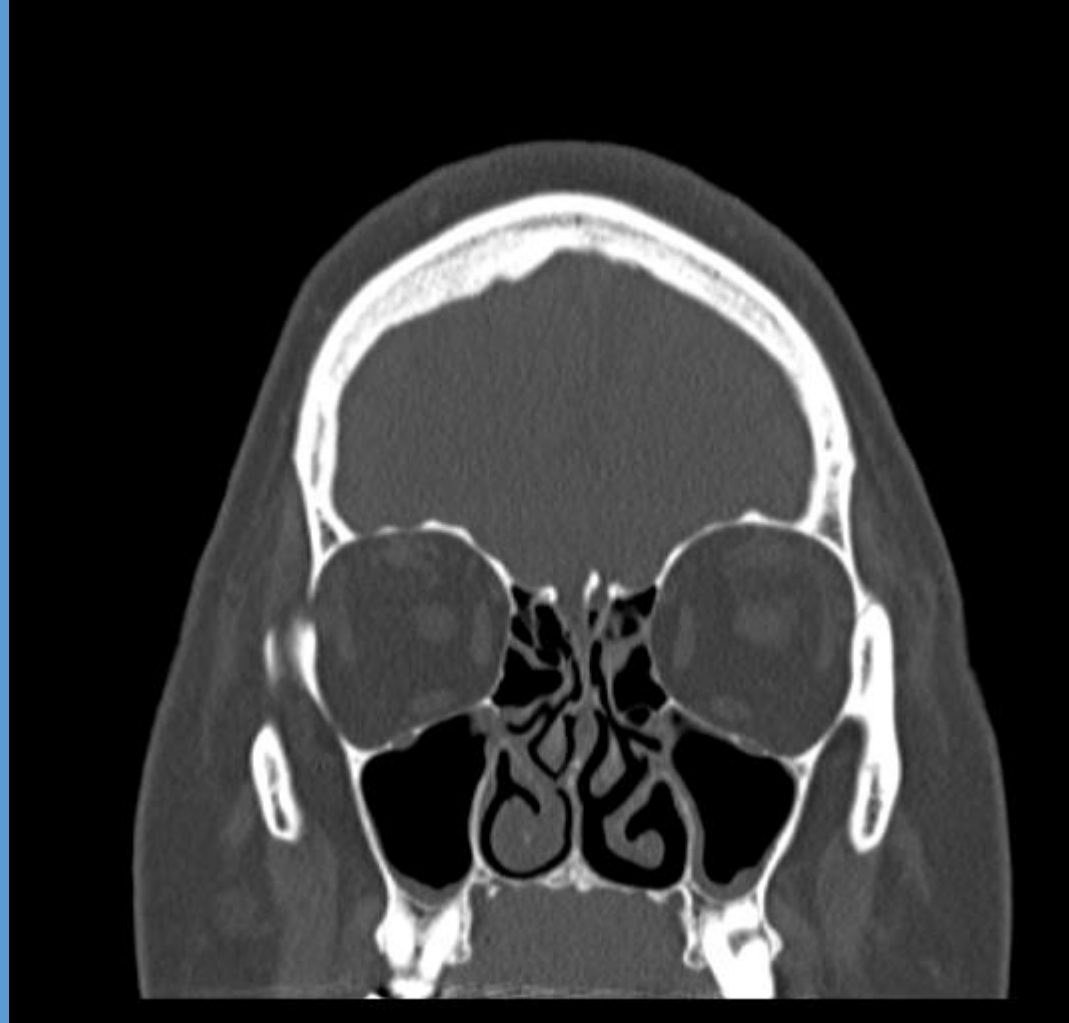
**Nasal obstruction, OSA, loud snoring, dry mouth. Ongoing for several years, most of his life.**





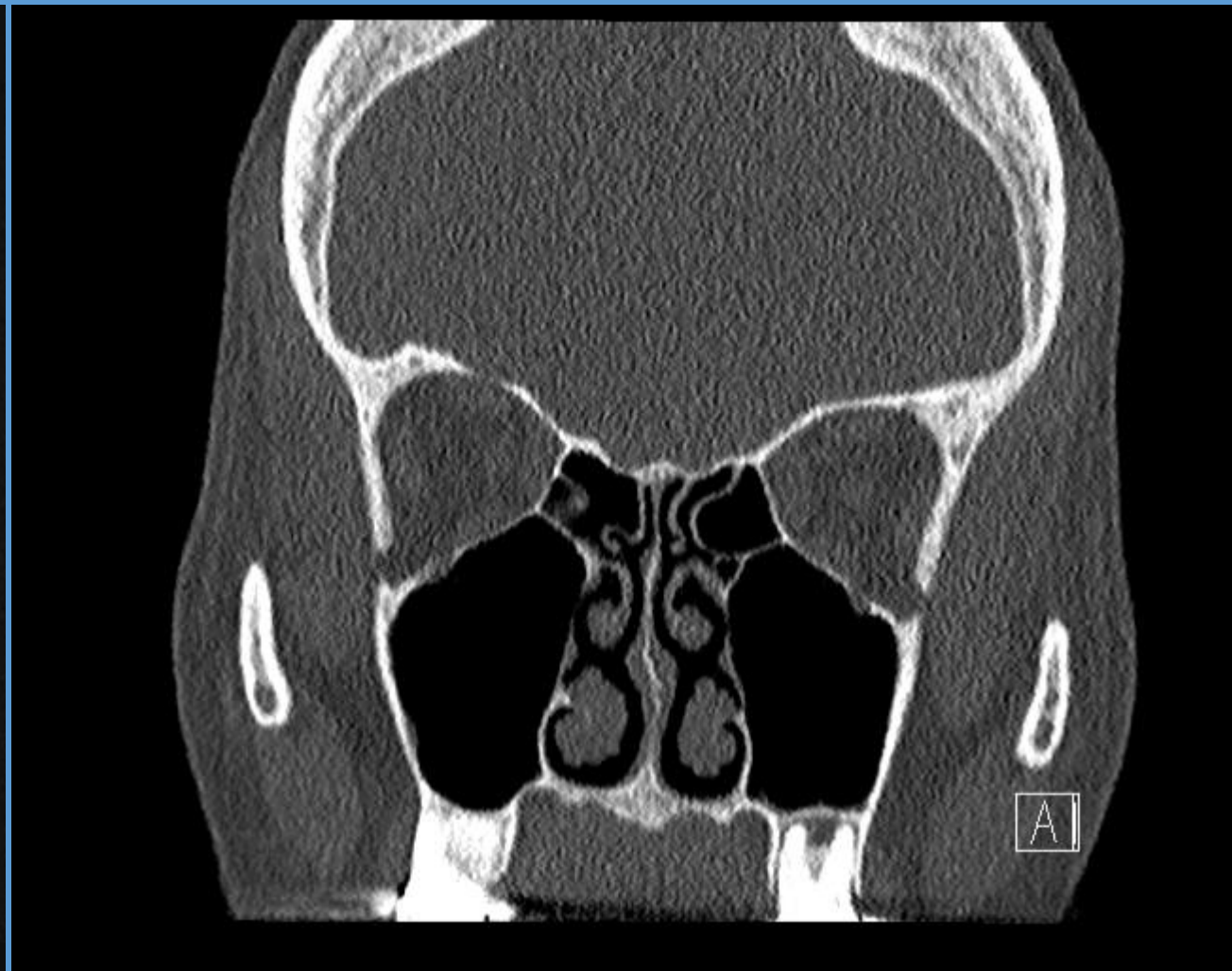
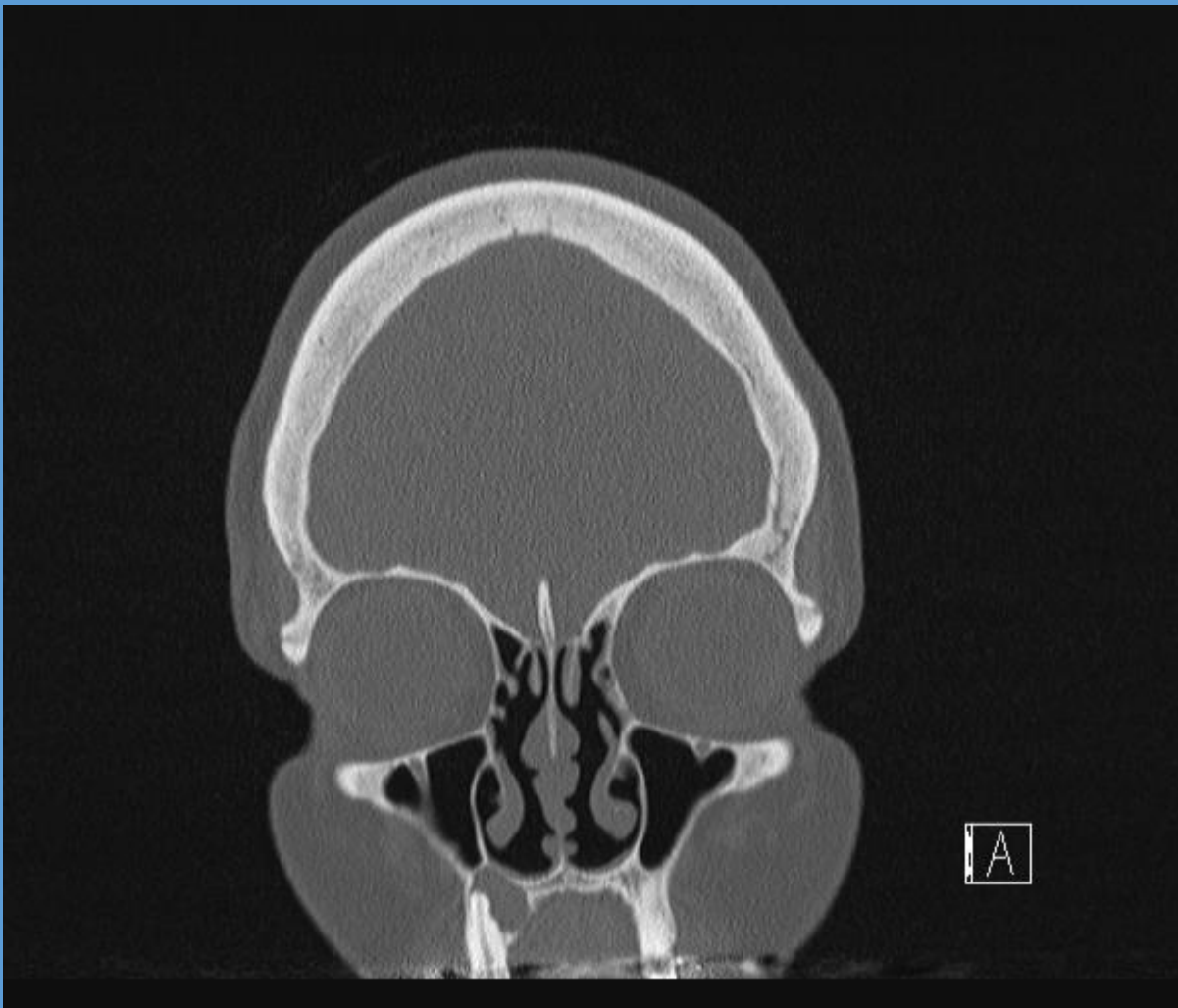
**59 y.o. female referred for consultation by PCP regarding chronic/recurrent sinusitis. Has had sinus problems/symptoms dating back for most of her life.**

**Baseline daily symptoms include congestion, nasal drainage, sinus pain and pressure, decreased sense of smell, upper tooth pain, fatigue, general malaise and all worse on the left than right.**





**Sinus complaints, no tooth pain**



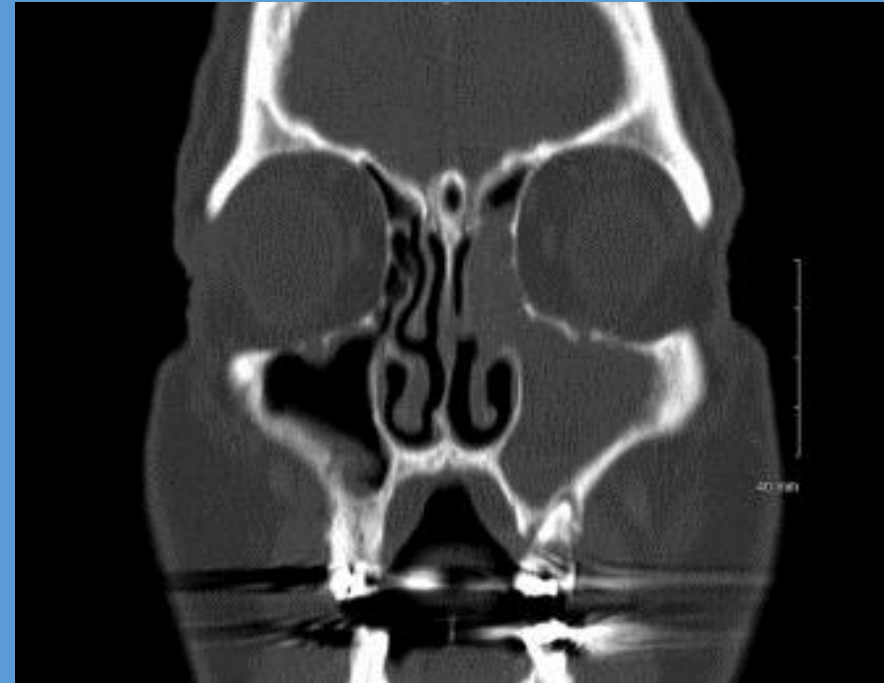
## Odontogenic sinusitis: A review of the current literature

### Objectives:

To present current literature on the topic of odontogenic sinusitis.

### Data Source:

PubMed literature search for odontogenic sinusitis.



**Results:** Odontogenic sinusitis is an inflammatory condition of the paranasal sinuses that is the result of dental pathology, most often resulting from prior dentoalveolar procedures, infections of maxillary dentition, or maxillary dental trauma. Infections are often polymicrobial with an anaerobe-predominant microbiome requiring special considerations for antimicrobial therapy. Medical management and treatment of the underlying dental pathology remains a critical initial step in the treatment of odontogenic sinusitis, however recent literature suggests that a significant portion of patients may require endoscopic sinus surgery for successful disease resolution.

**Conclusions:** This review describes the essential epidemiological and etiological factors, relevant clinical findings and diagnostic modalities, microbiologic and antimicrobial considerations, as well as the medical and surgical treatment approaches commonly utilized for the management of odontogenic sinusitis.

## Treatment options for odontogenic maxillary sinusitis: a review

**OBJECTIVE:** The aim of this article is to review the **main treatment options for odontogenic sinusitis** that are used today.

**MATERIAL AND METHODS:** Search on PubMed, Cochrane Library, PMC, Science Direct data bases. For a literature review search keywords were used: odontogenic sinusitis, odontogenic maxillary sinusitis treatment OR diagnosis, maxillary sinusitis of dental source OR dental origin OR etiology.

**RESULTS:** **2886 articles** were found in the databases using keywords. After duplicate citations screened, inclusion/exclusion criteria applied, excluded articles after titles, summaries and full-text reading 25 articles were included in the literature review.

**CONCLUSION:** Although clinical symptomatology is not conspicuous among other types of sinusitis, the **odontogenic maxillary sinusitis treatment regimen is different. It consists of eliminating dental infection and management of sinusitis.** The usage of Caldwell-Luc approach is limited these days and recommended only when a better access to sinus is needed, for example, removing large foreign bodies. Endoscopic sinus surgery is widely used these days to remove the inflamed sinus mucosa, foreign bodies, displaced teeth, while preserving physiological function of the sinus. Sometimes dental infection removal alone is sufficient to resolve the odontogenic maxillary sinusitis, but sometimes concomitant endoscopic sinus surgery or Caldwell-Luc approach is necessary for full resolution.

## Comparison of Sino-Nasal Outcome Test 22 Symptom Scores in Rhinogenic and Odontogenic Sinusitis

**Background:** **Odontogenic maxillary sinusitis (OMS)** and rhinogenic sinusitis (RS) are the main types of chronic rhinosinusitis (CRS) and have a significant impact on health-related quality of life (HRQL), but the difference in HRQL and symptom presentation between them has not been specifically evaluated to date.

**Objective:** Our aim was to compare patterns of symptoms and HRQL disease-specific domains in patients affected with these 2 types of CRS.

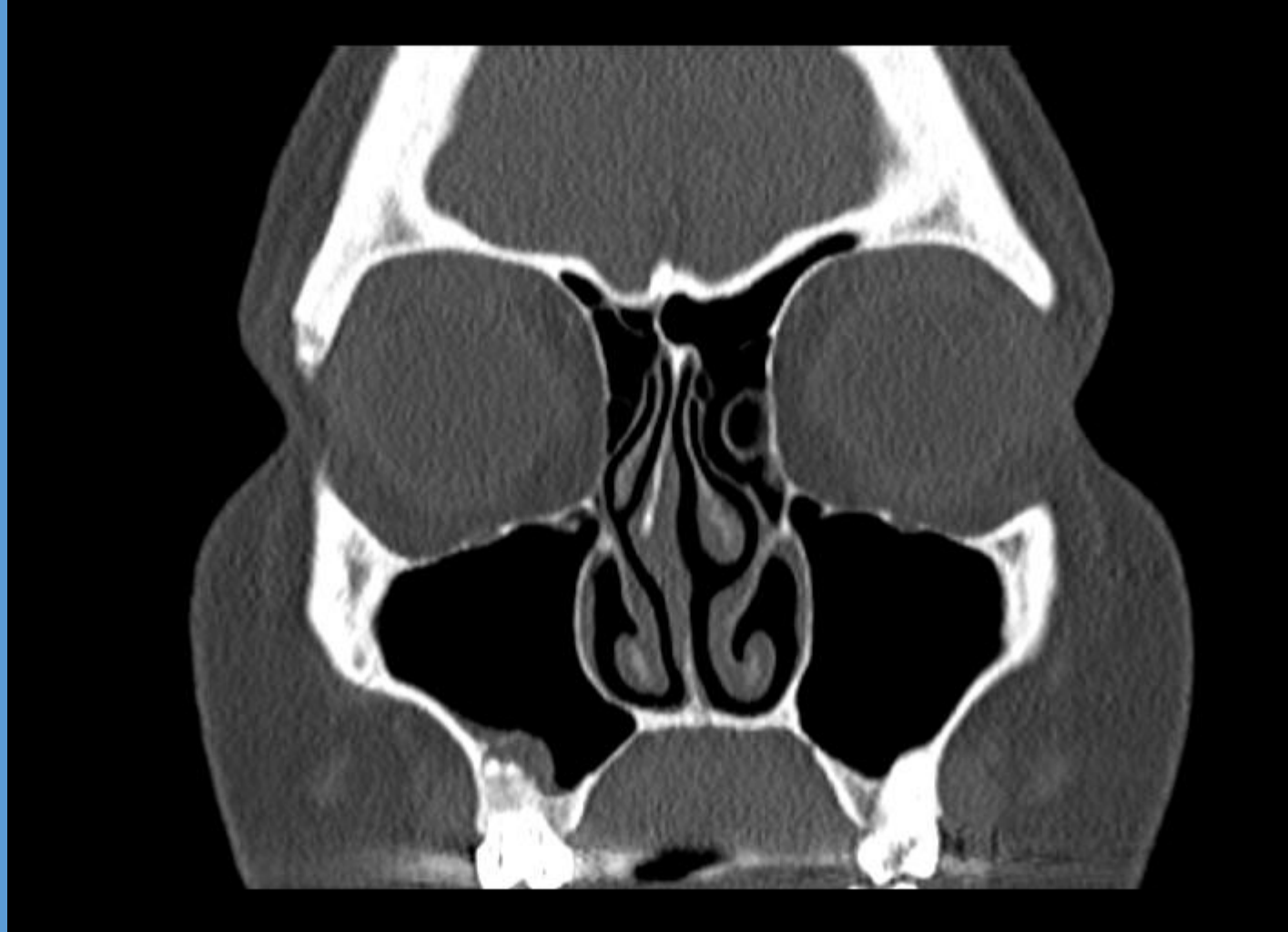
**Methods:** A group of 201 patients with CRS (99 with rhinogenic and 102 with odontogenic origin) completed the **Sino-Nasal Outcome Test 22 (SNOT-22)** questionnaire before treatment. Data sets were analyzed by using principal component analysis (PCA) to identify a set of symptom components together with the items excluded from PCA, which were then analyzed for differences between patients with OMS and RS.

**Results:** PCA of SNOT-22 items identified 5 components: "rhinologic," "extranasal rhinologic," "ear/facial," "sleep and functional disturbance," and "emotional disturbance." Sneezing was excluded from PCA and treated as separate outcome variable and was significantly worse in RS patients. Patients with OMS scored significantly higher scores with regard to emotional disturbance, while RS patients scored significantly worse in sleep and functional disturbance. **The extra symptom "malodor" was the most different symptom and was significantly worse in OMS patients. The total SNOT-22 score was not significantly different between the groups.**

**Conclusion:** With controlling of covariates that may influence the severity of the disease, this study showed some significant differences in symptom patterns and HRQL impairment between patients with OMS and RS. **Malodor is the most characteristic feature of OMS. Therefore, OMS should always be suspected in patients complaining of bad breath.**

**34 y.o. female referred for consultation by her dentist regarding chronic/recurrent sinusitis, more recent question of focal sinusitis playing a role in tooth pain.**

**In the past had had quite a bit of sinus trouble, living in different states, but moved here and has actually done better. Then recently had some dental pain, eval showed some dental issues and got root canal on the right, but still with pain on the left. Has had abx, as well as sudafed and long term flonase.**



## Chronic sinusitis of odontogenic origin due to an undiagnosed displaced root fragment in the maxillary sinus and the role of cone beam computed tomography in successful management

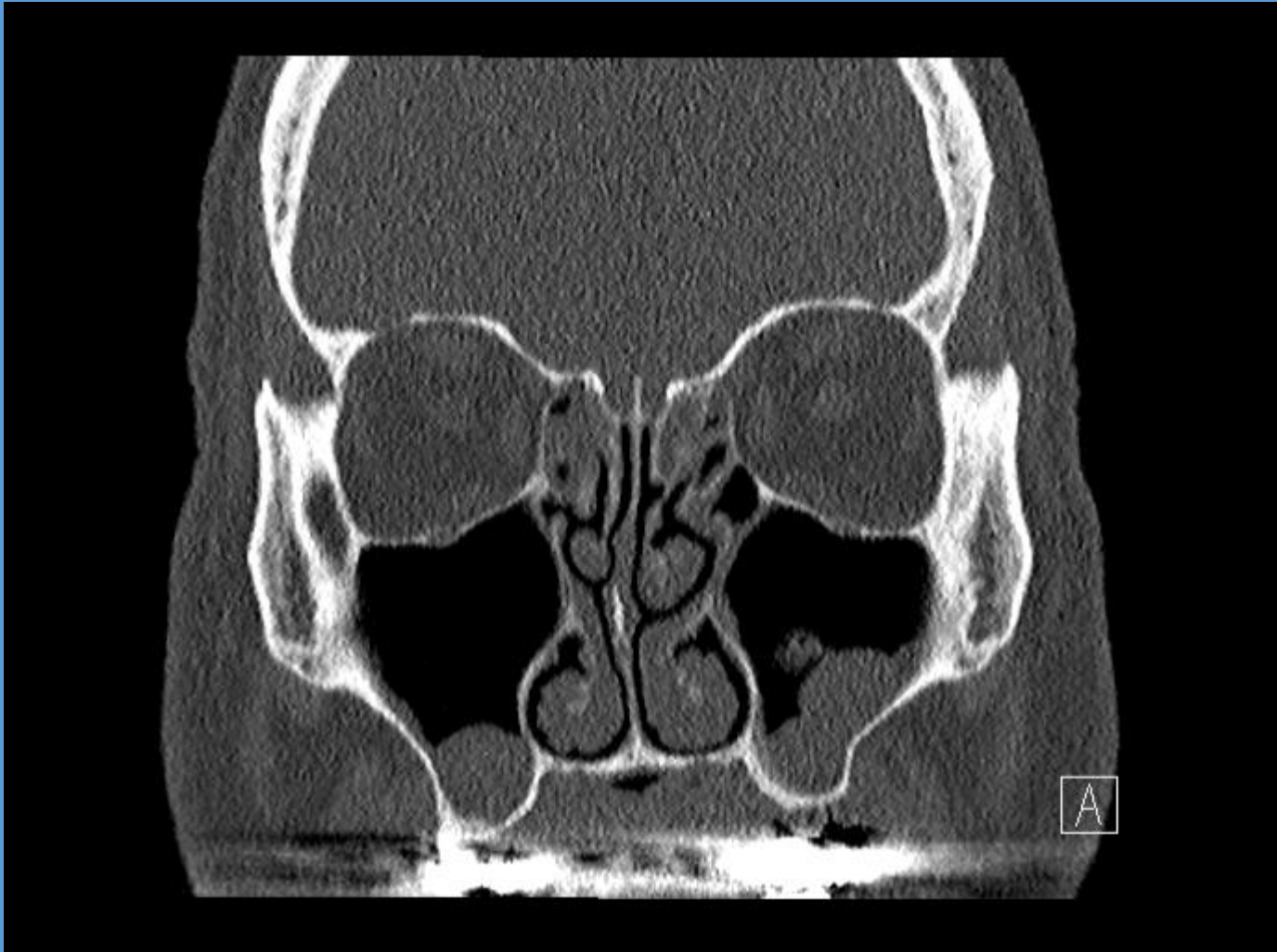
### Abstract

Radiographic imaging is an important criteria in diagnosis, treatment planning, and follow-up of an endodontic treatment. When clinicians encounter with diagnostic difficulties and persistent symptoms, the need for advanced diagnostic aids, especially imaging methods, become imperative and essential. This paper reports a case, in which **primary endodontic therapy having failed, the patient had persisting symptoms such as pain, swelling, and draining sinus along with signs and symptoms of maxillary sinusitis**. Advanced diagnostic aids such as **Cone Beam Computed Tomography was useful** in accurate identification of the etiology, which was a **fractured mesiobuccal root tip of maxillary molar**. This is the first reported case, in which the **fractured root tip has migrated to the maxillary sinus**, during primary endodontic treatment, through the perforated antral floor causing odontogenic sinusitis. The operating microscope helped in the successful completion of endodontic retreatment along with fractured root fragment retrieval.

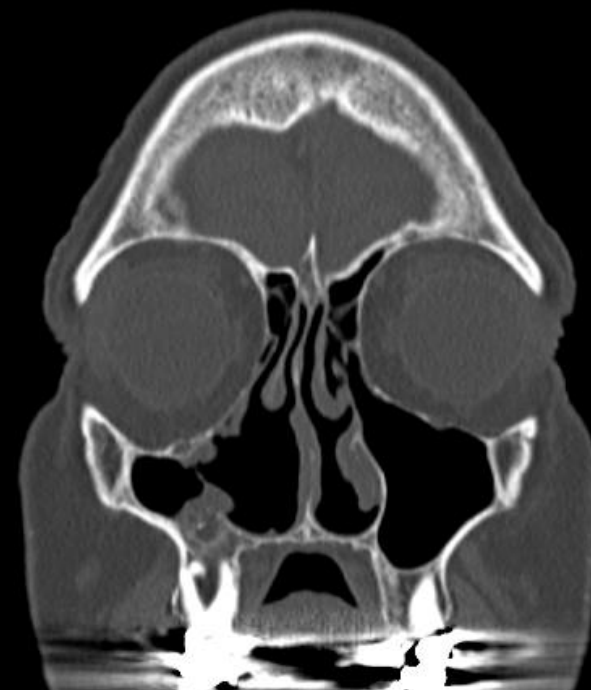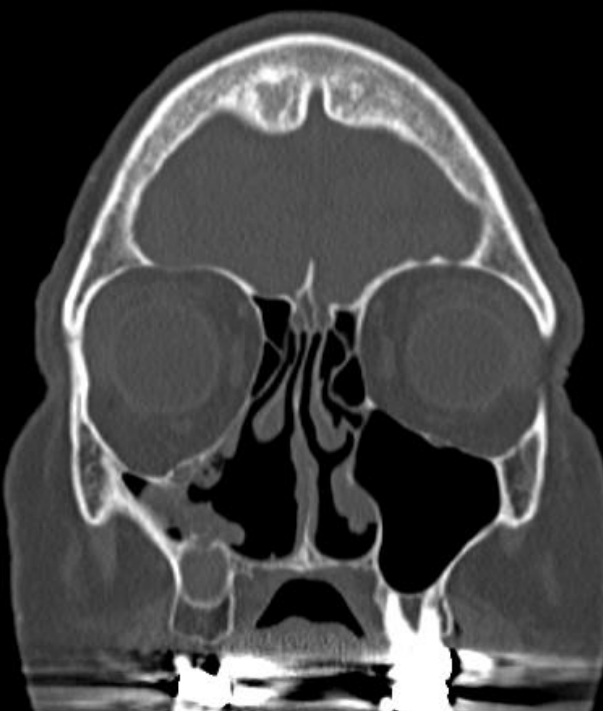

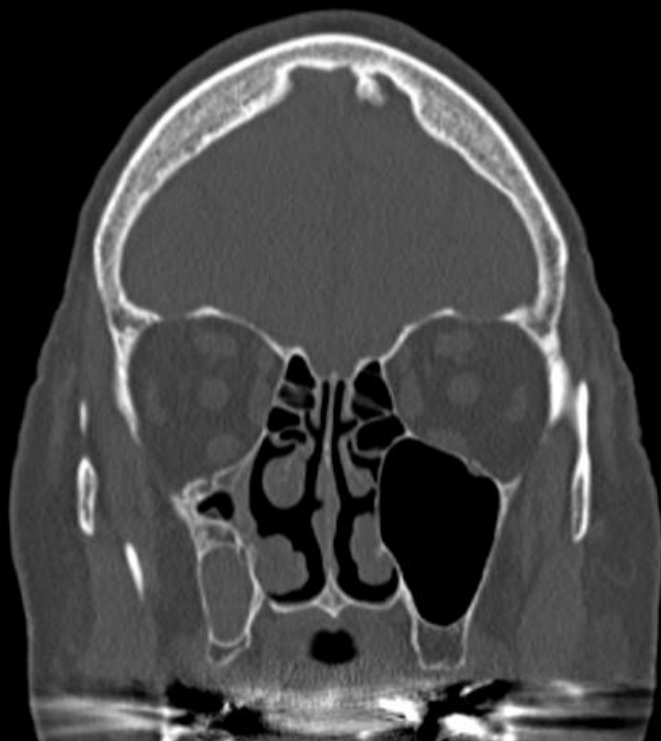
**56 y/o male with chronic sinus sx for past 3 months.**

**Preventing him from getting his dental implant done, dentist wants clear sinuses prior to the procedure.**

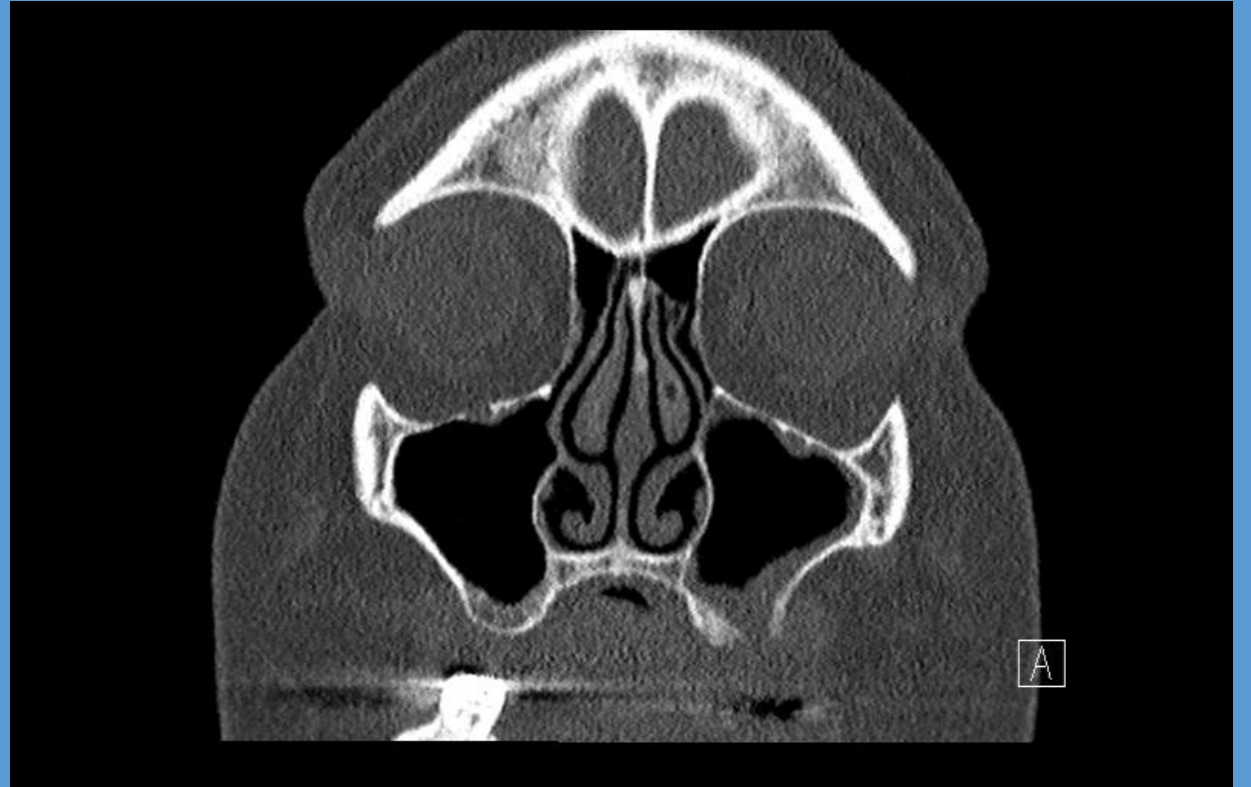
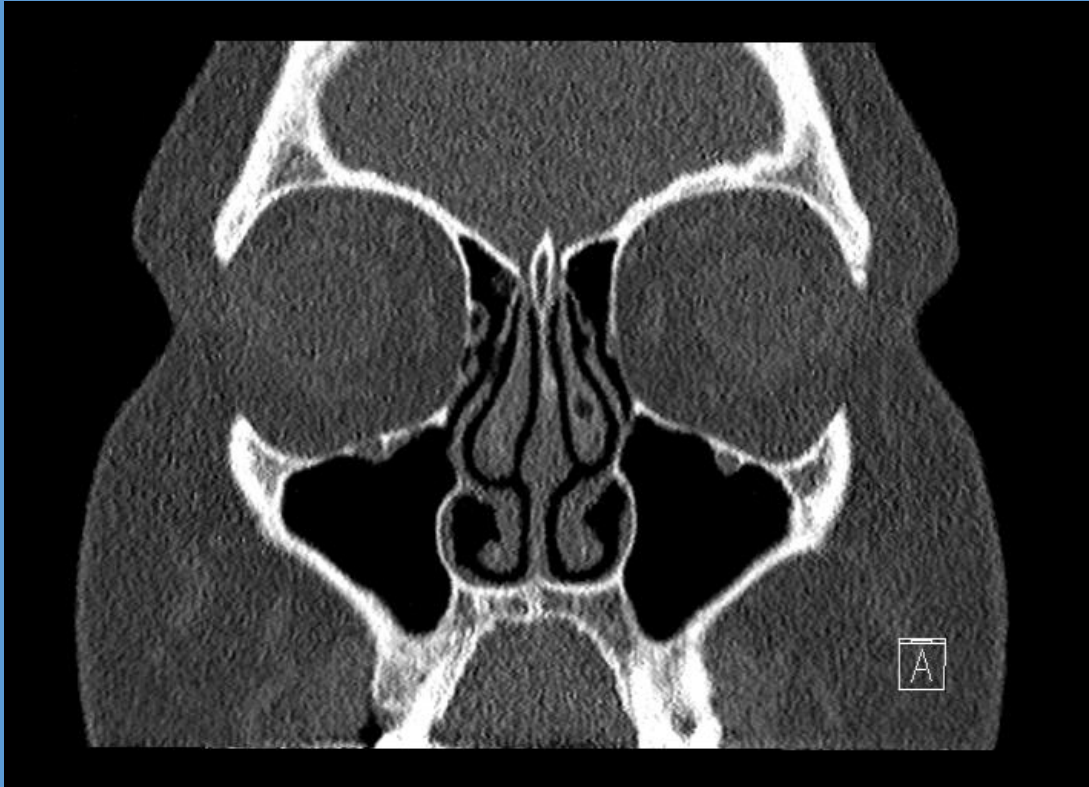


?



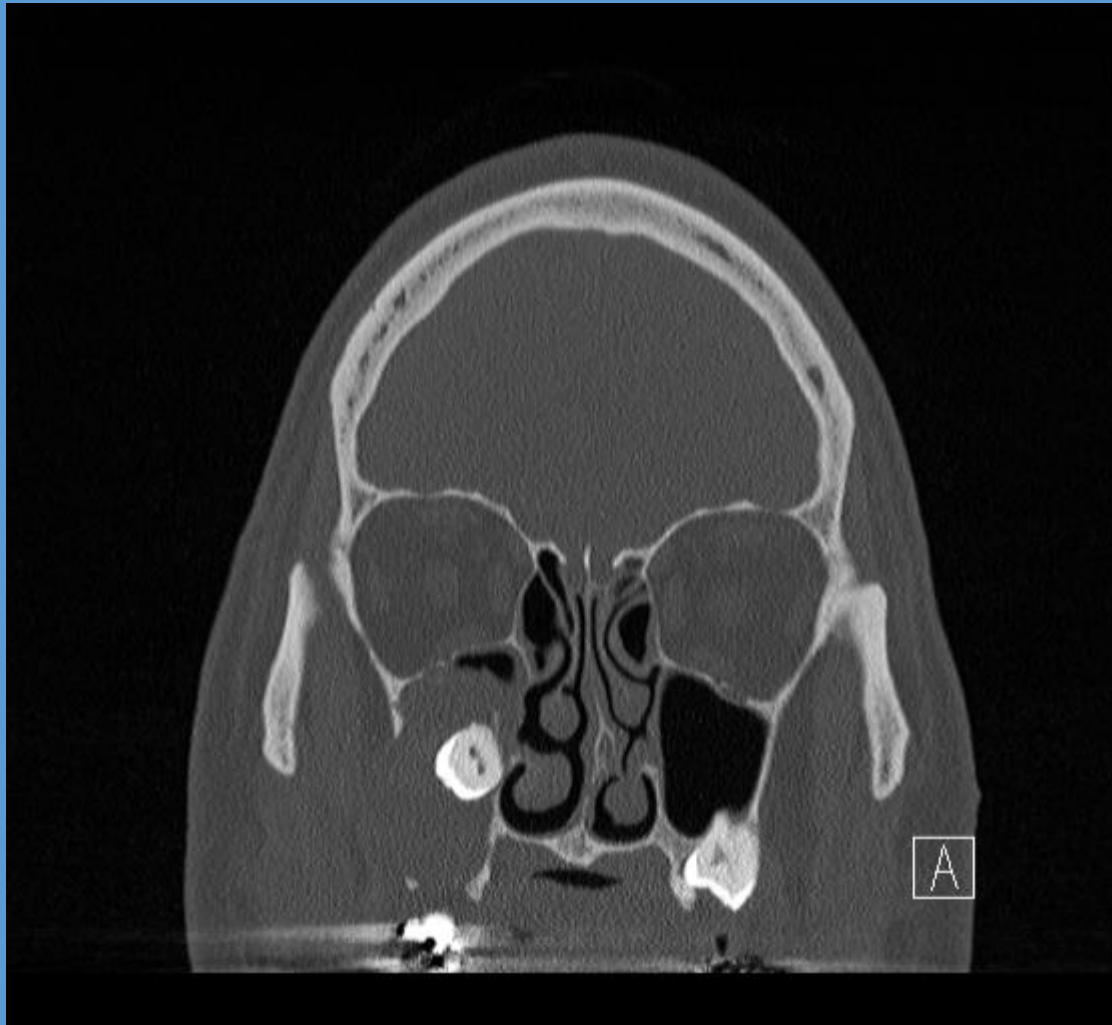


# Oroantral fistula

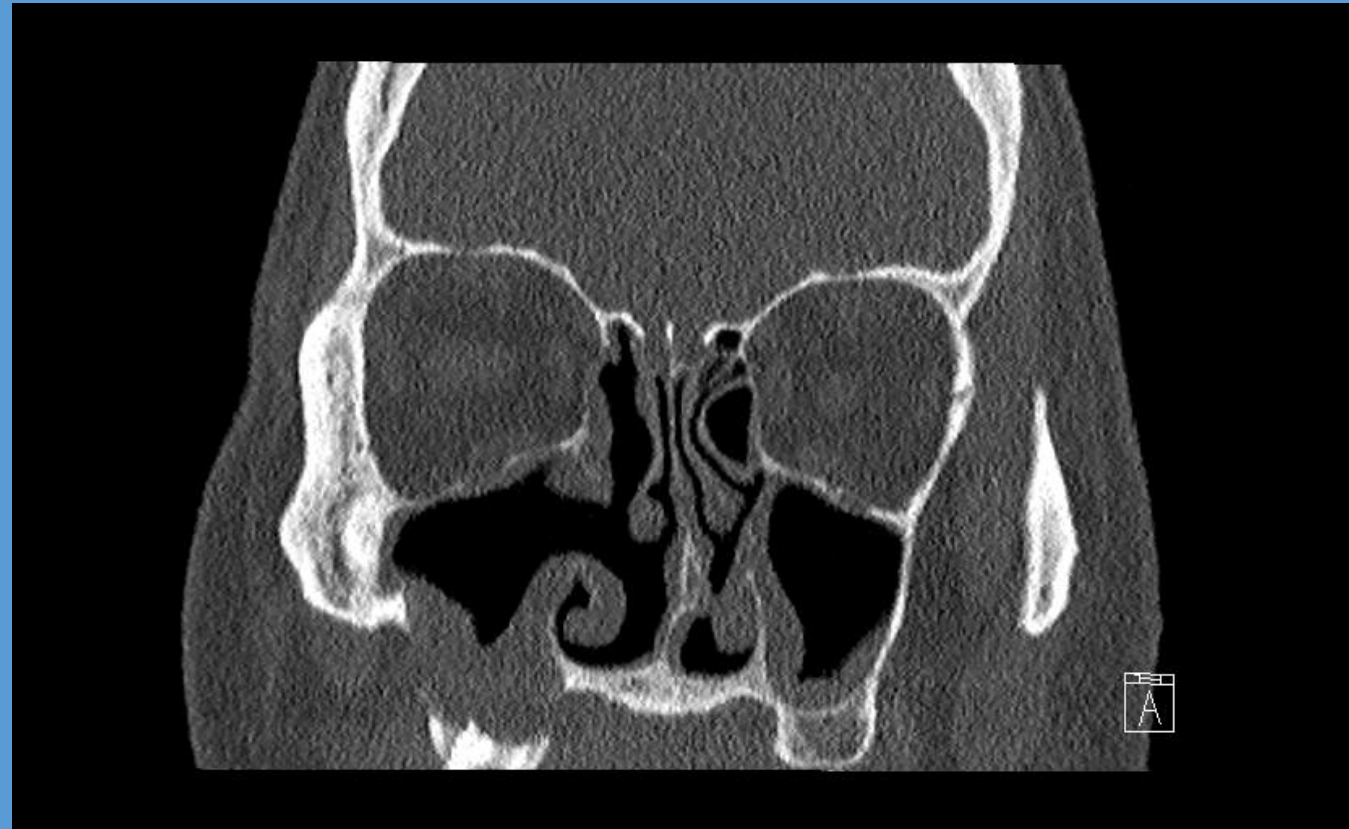


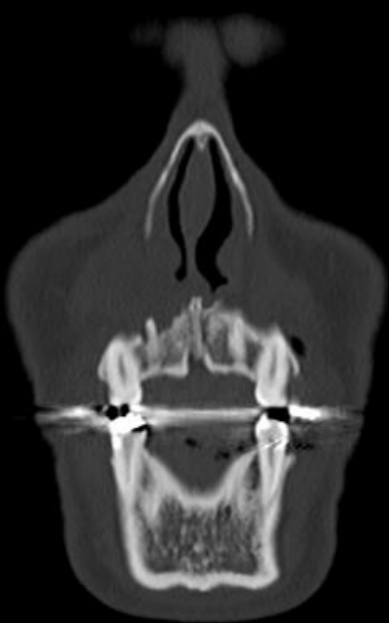# 53 y/o male with right facial pain – dentigerous cyst

preop



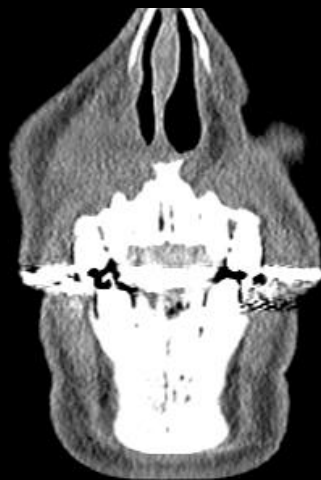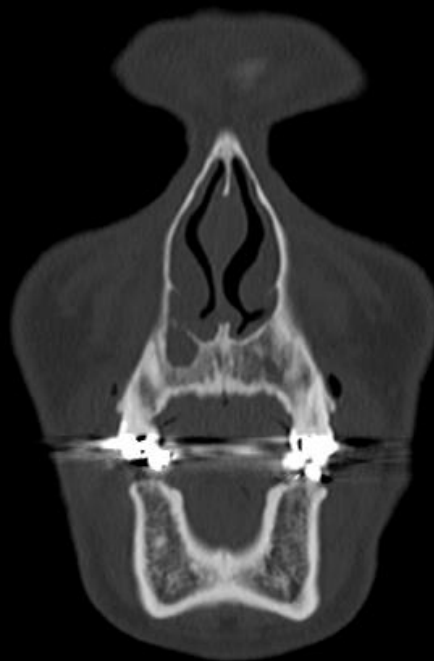
2 months postop





## IMPRESSION:

1. Right lateral maxillary incisor (tooth 7). Apical lucency consistent with periapical abscess. Accompanying soft tissue edema is present.



Or....nasolabial cyst?

## Brain abscess following dental implant placement via crestal sinus lift - a case report

**PURPOSE:** To describe a rare case of odontogenic brain abscess.

**MATERIALS AND METHODS:** A healthy, 35-year-old male had two dental implants placed in a simultaneously augmented maxillary sinus. One implant failed and the patient developed a maxillary sinusitis that failed to improve following antibiotic treatment at home. The neglected sinus infection led to formation of a brain abscess. The patient was hospitalised only when he had pan sinusitis with neurological signs. Symptoms were headache attacks, a subfebrile fever and a purulent secretion from the left nostril. The osteomeatal complex was blocked, the maxillary sinus was filled with pus and the Schneiderian membrane thickened. The patient was treated with intravenous antibiotic treatment. Computerised tomography (CT) and magnetic resonance imaging (MRI) scans and functional endoscopic sinus surgery (FESS), were implemented. When his conditions worsened, the patient underwent a left frontal mini craniotomy.

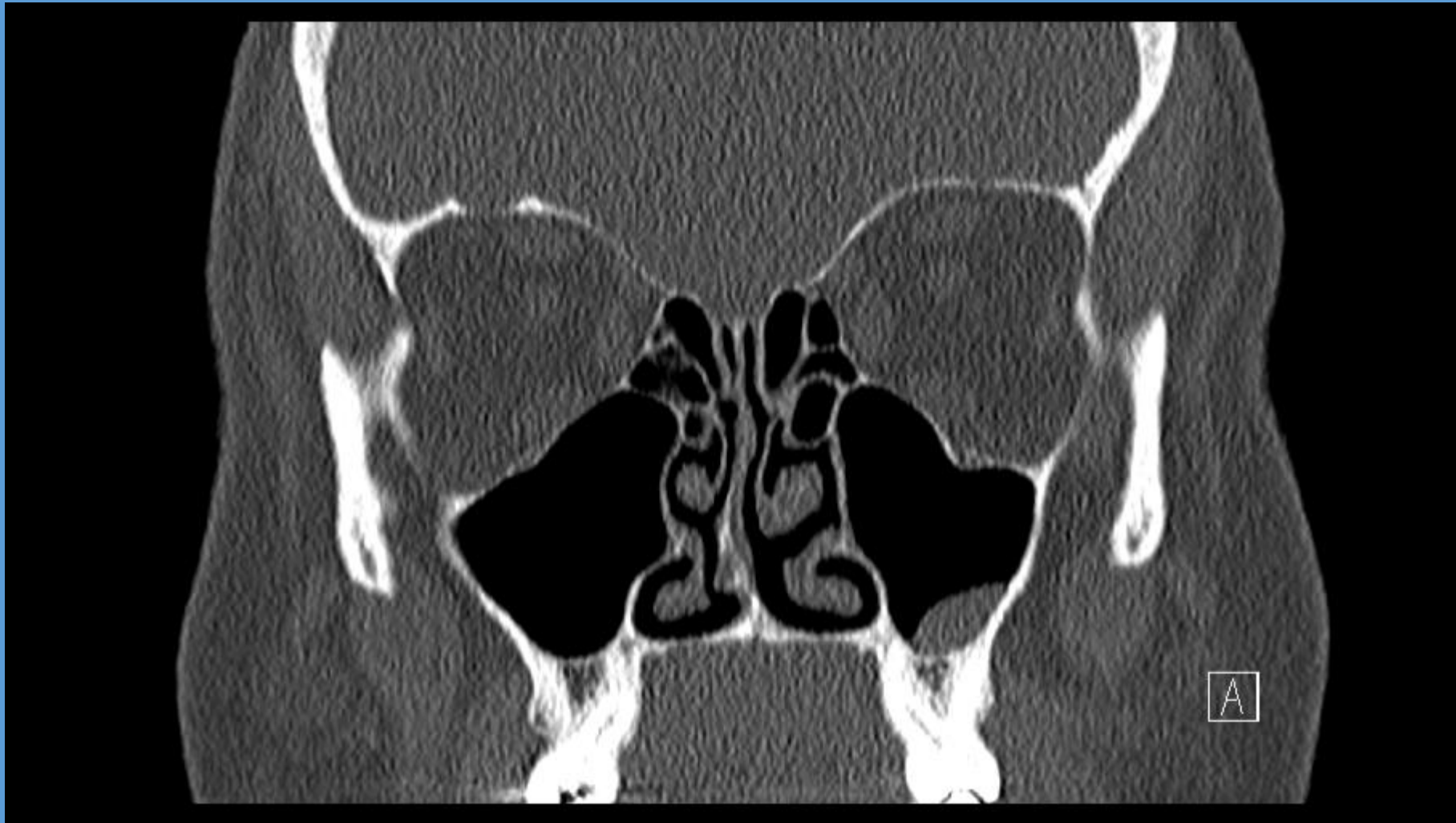**RESULTS:** Following the craniotomy and antibiotic treatment, there was a gradual resolution and the patient was dismissed after 2 months in hospital with no neurological deficit or signs of sinusitis.

**CONCLUSIONS:** Maxillary sinusitis following dental implant insertion and concomitant maxillary sinus elevation should be treated immediately and thoroughly since untreated sinusitis may cause life-threatening situations such as a brain abscess. In case of severe infection, clinicians should refer immediately the patient to hospital specialists.

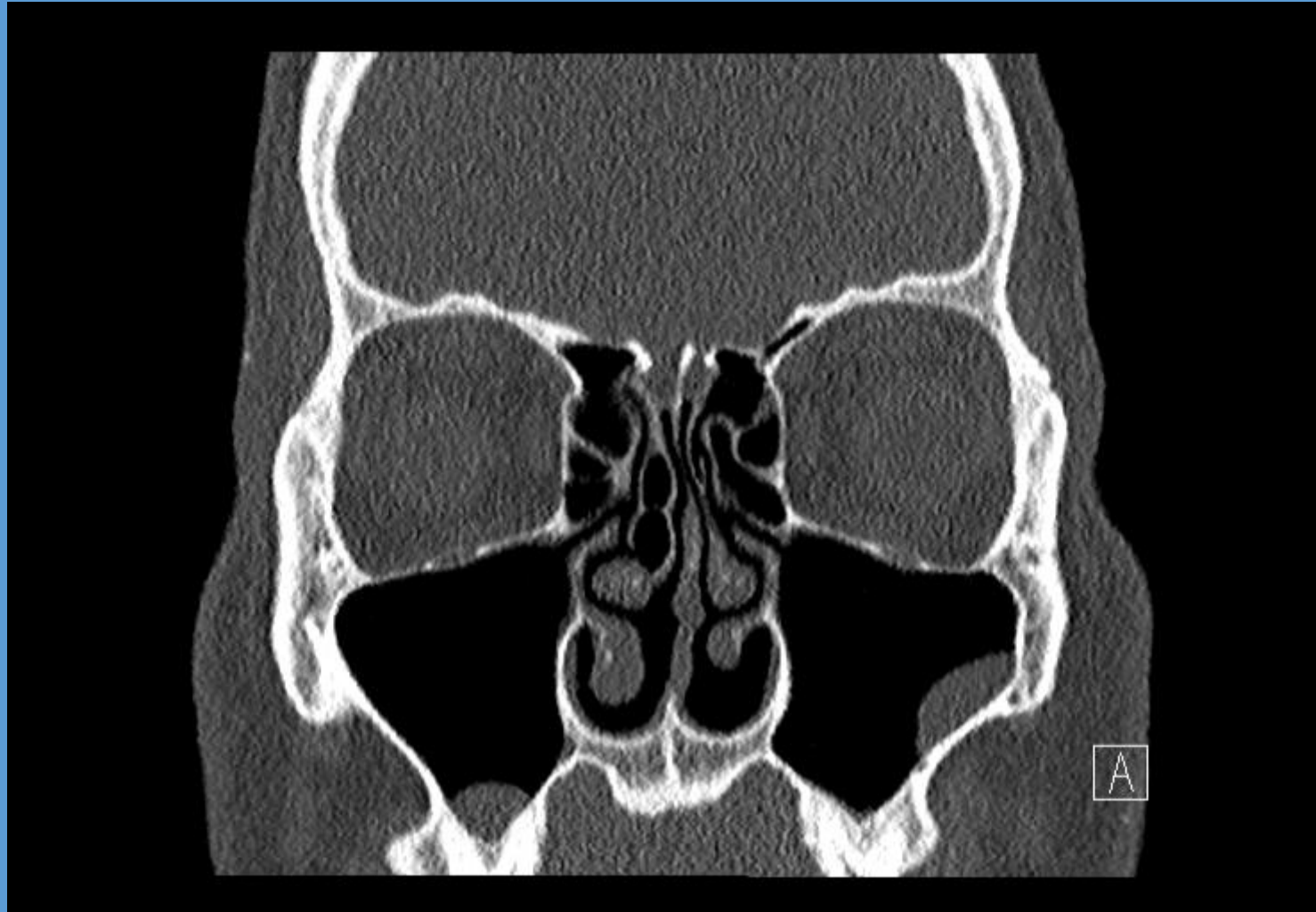


**54 y.o. female referred for consultation by her dentist regarding possible sinus polyps seen on dental films.**

**Mild sinus issues off and on for much of her life, but to this point not too bad, not too bothersome, always pretty self limited. Recent dental eval showed opacities in sinuses thought to possibly be sinus polyps.**



# Simple mucous retention cyst (MRC)



# Endoscopic Sinus surgery

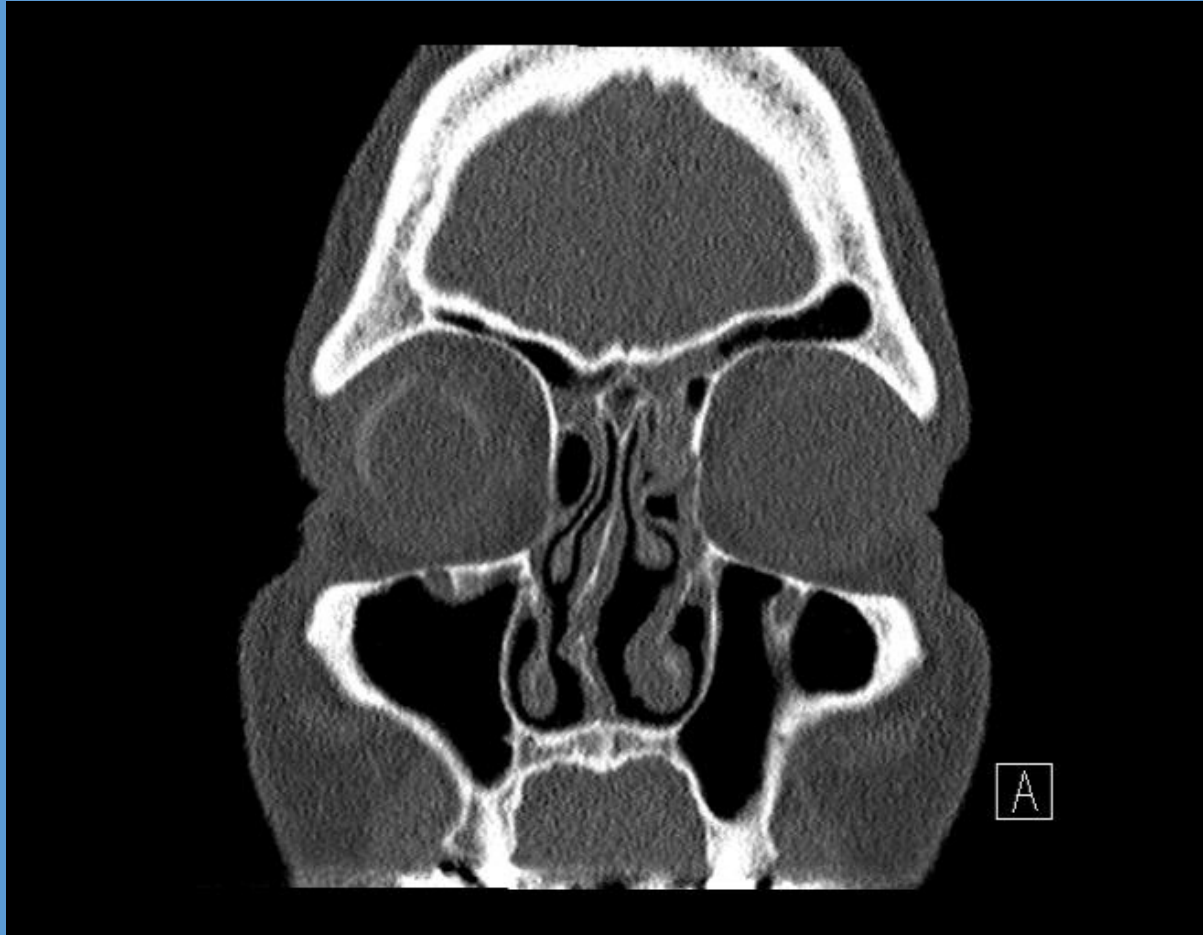
or...

“FESS” = Functional Endoscopic Sinus Surgery

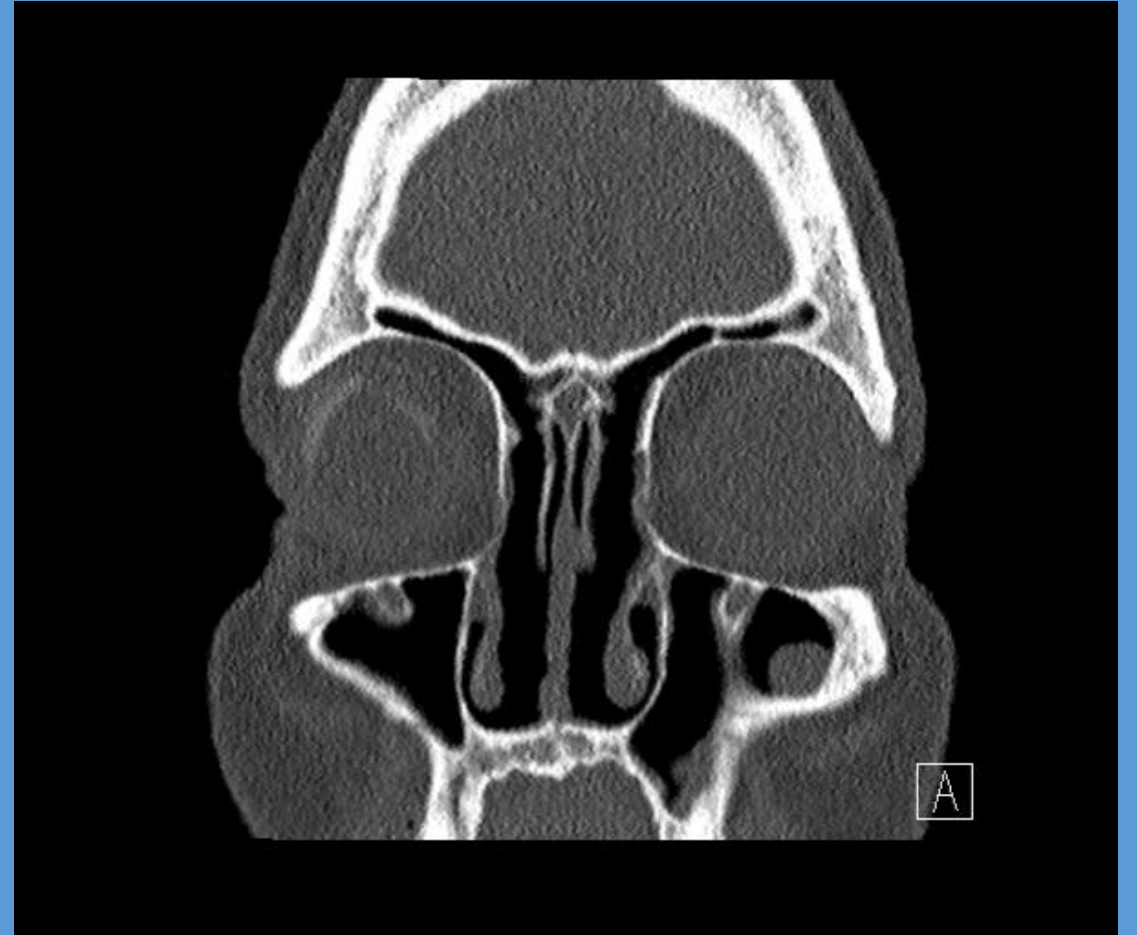
- Address involved sinuses
- Septoplasty
- Turbinate reductions

# Sinus Surgery (frontals)

Before



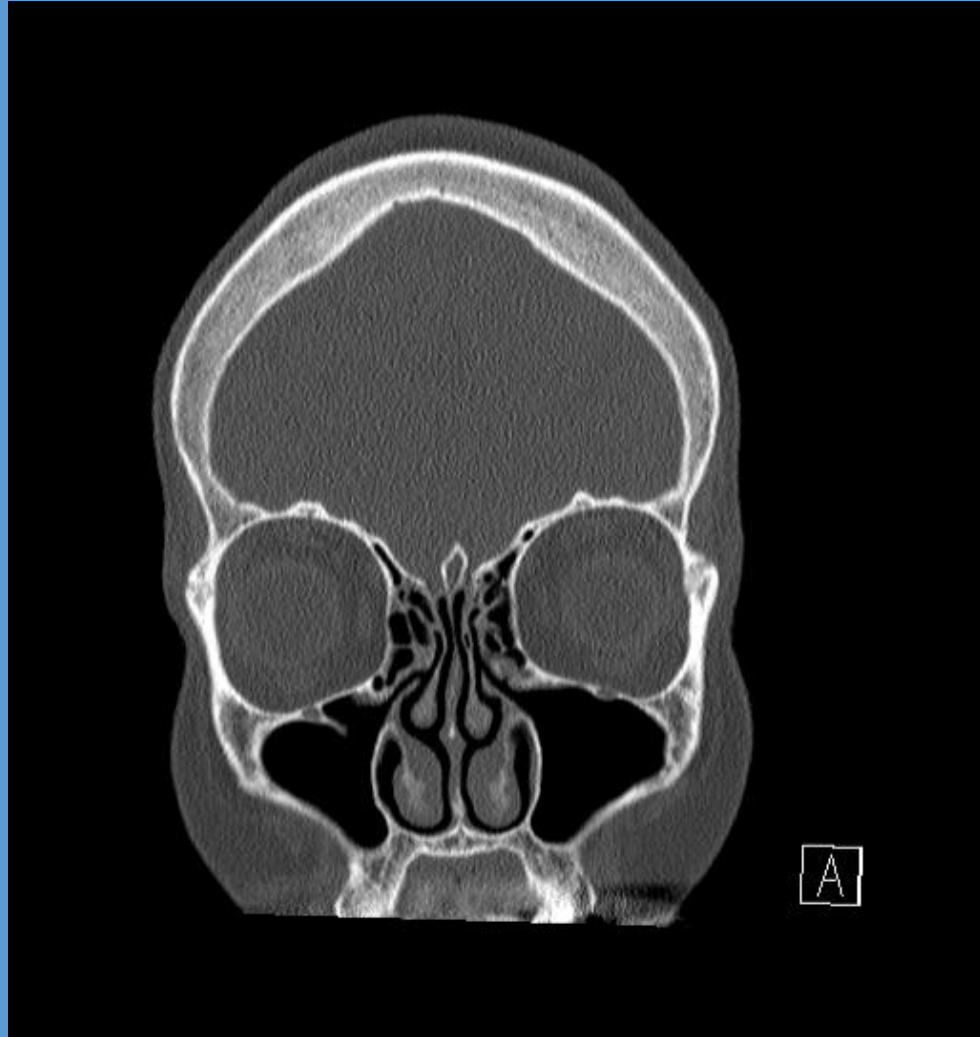
After



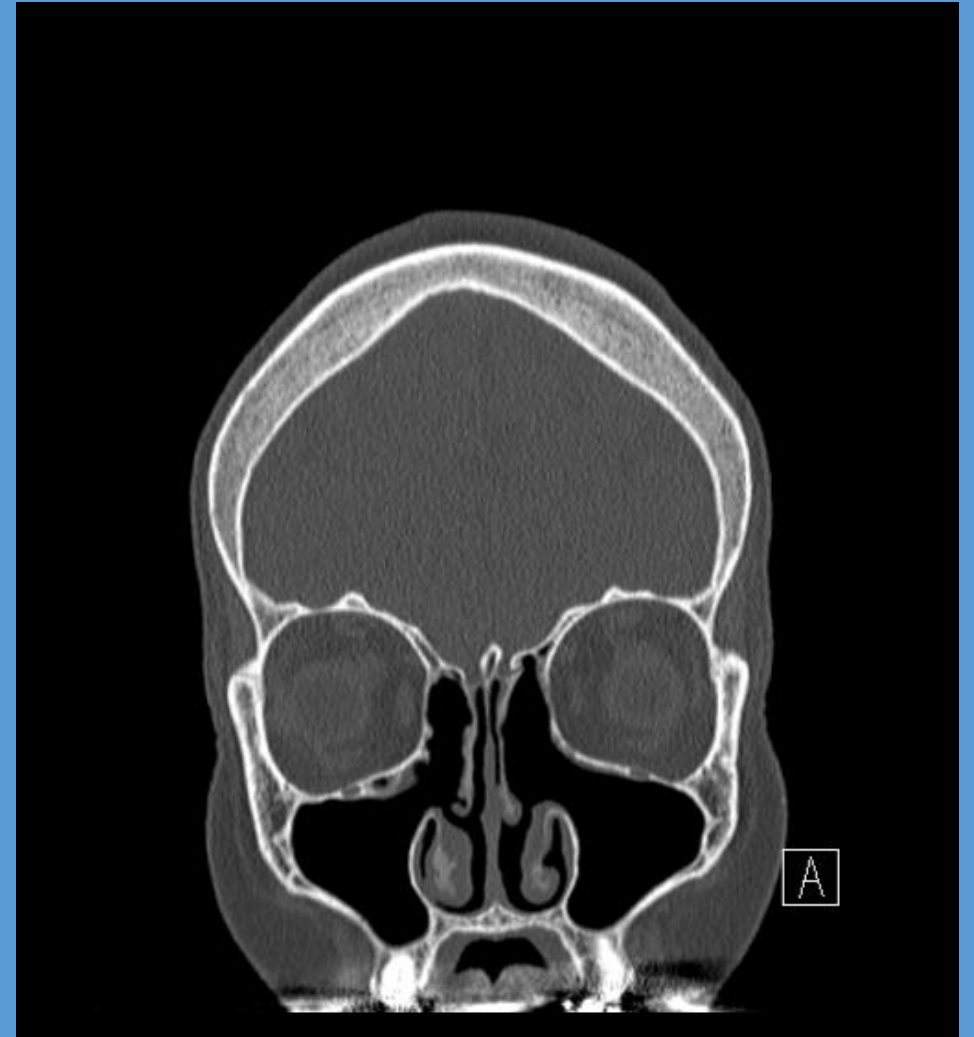


# Sinus Surgery (maxillary/anterior ethmoid)

Before

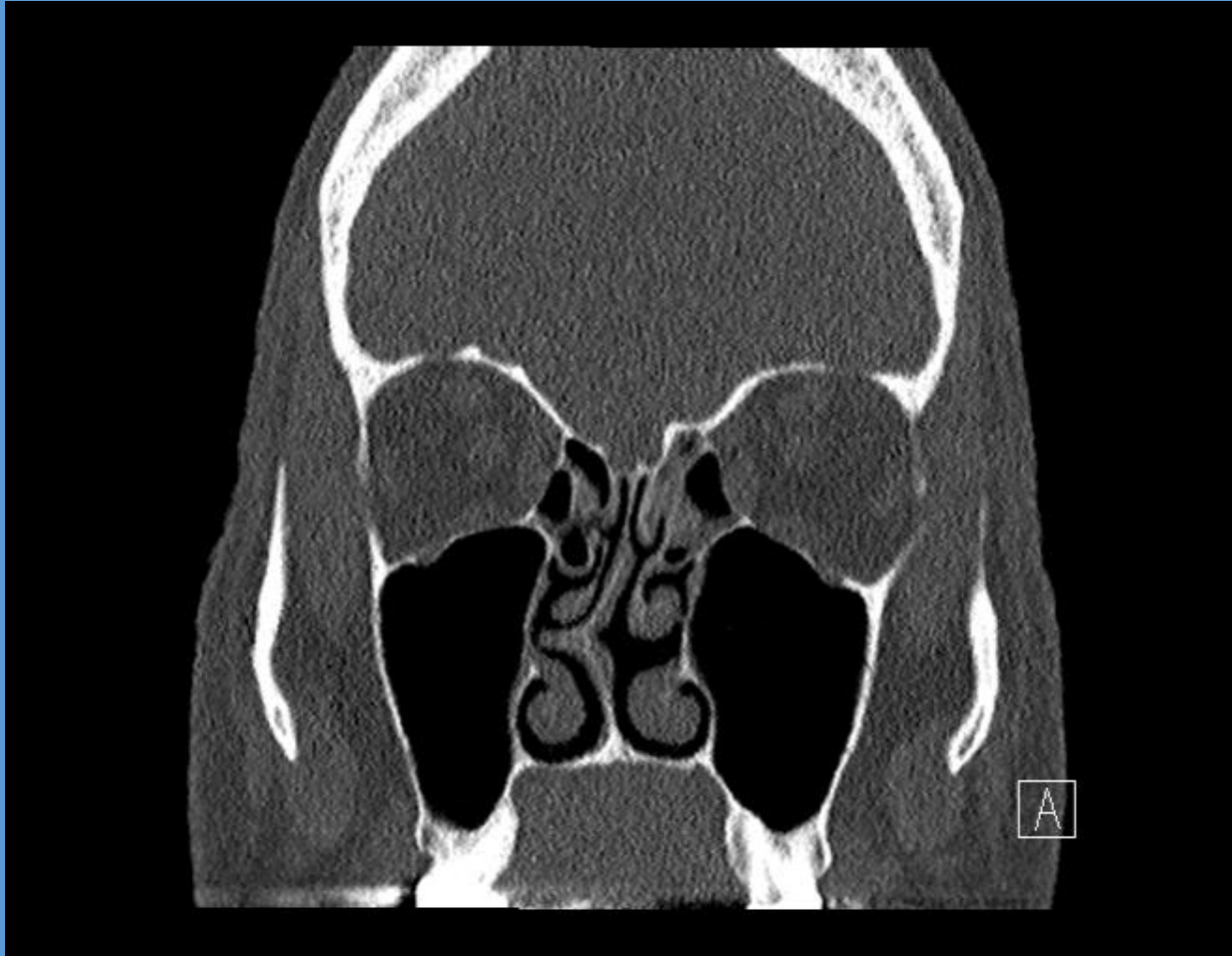


After

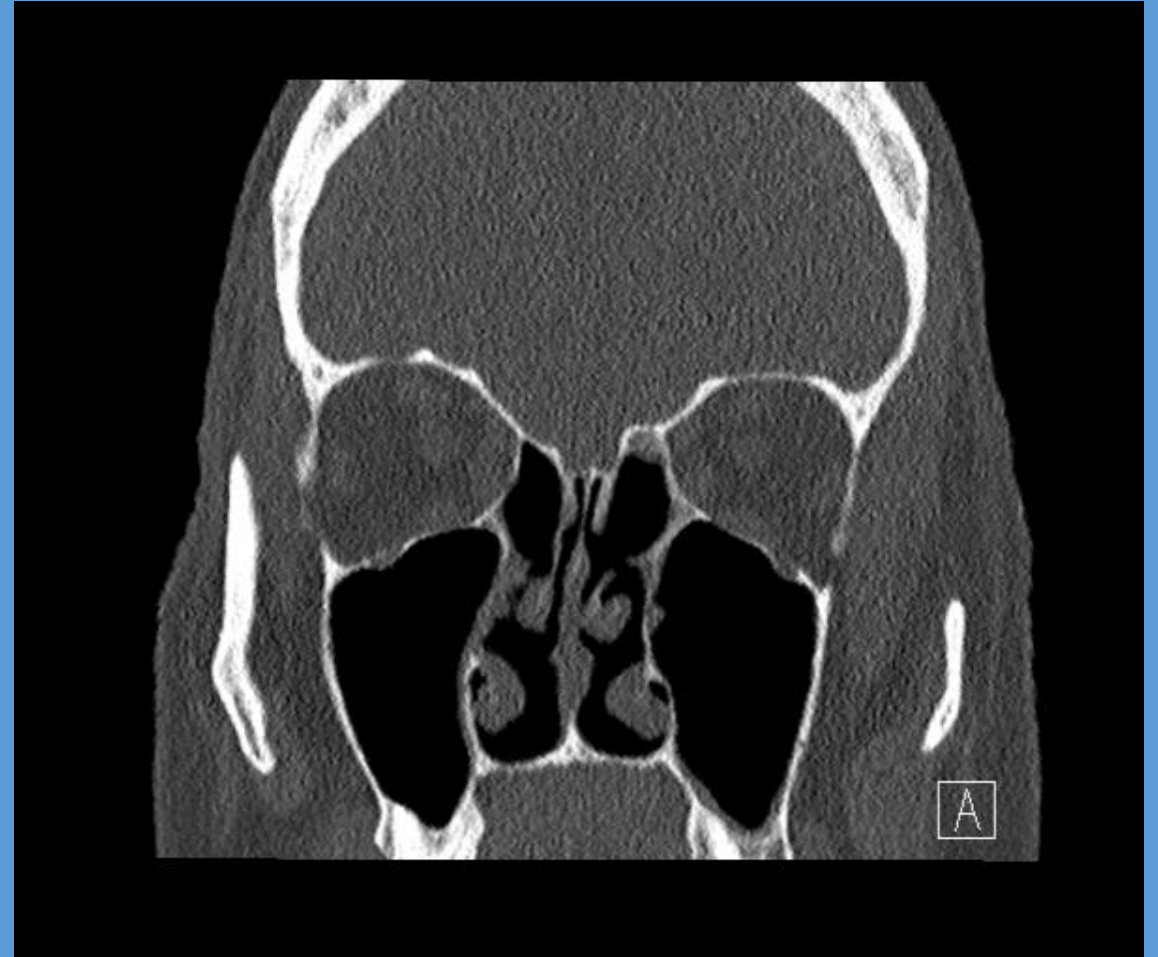


# Sinus Surgery (posterior ethmoid)

Before

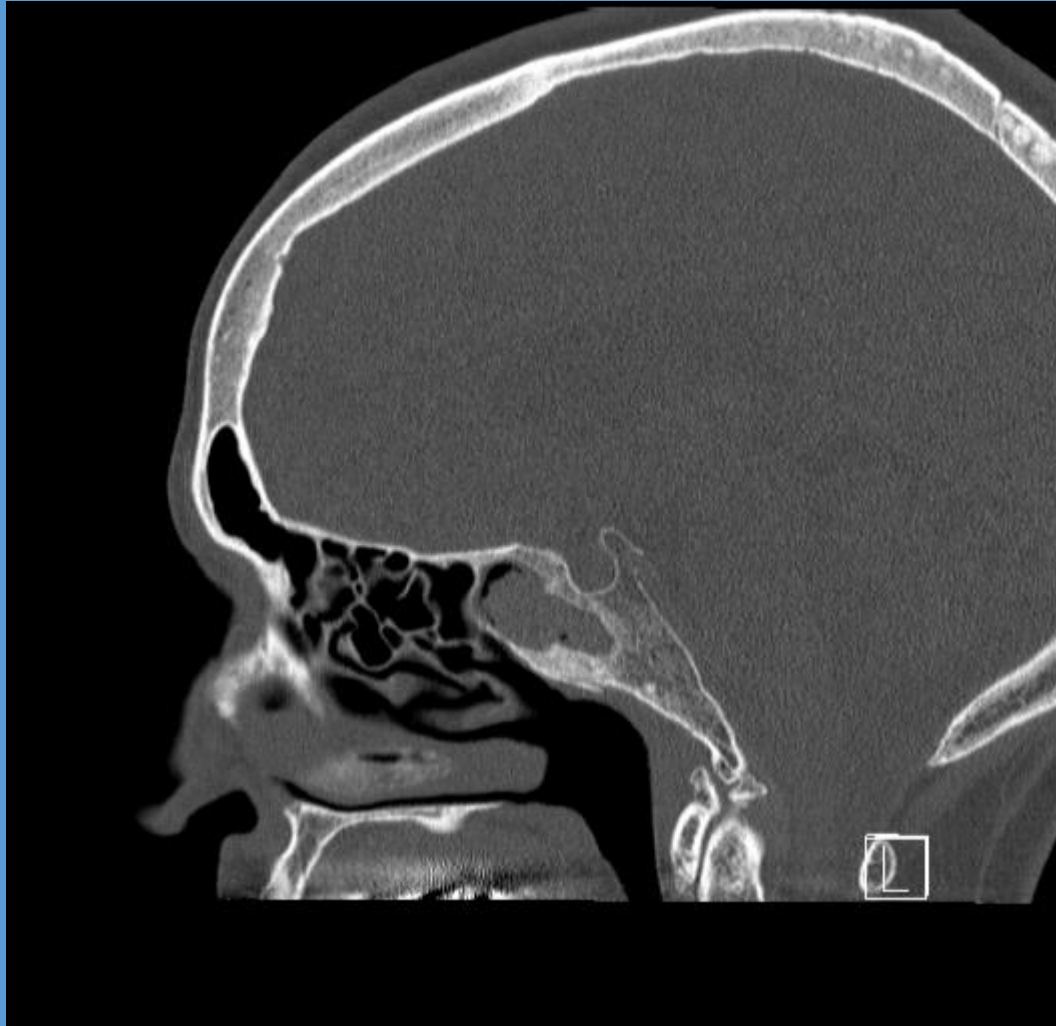


After

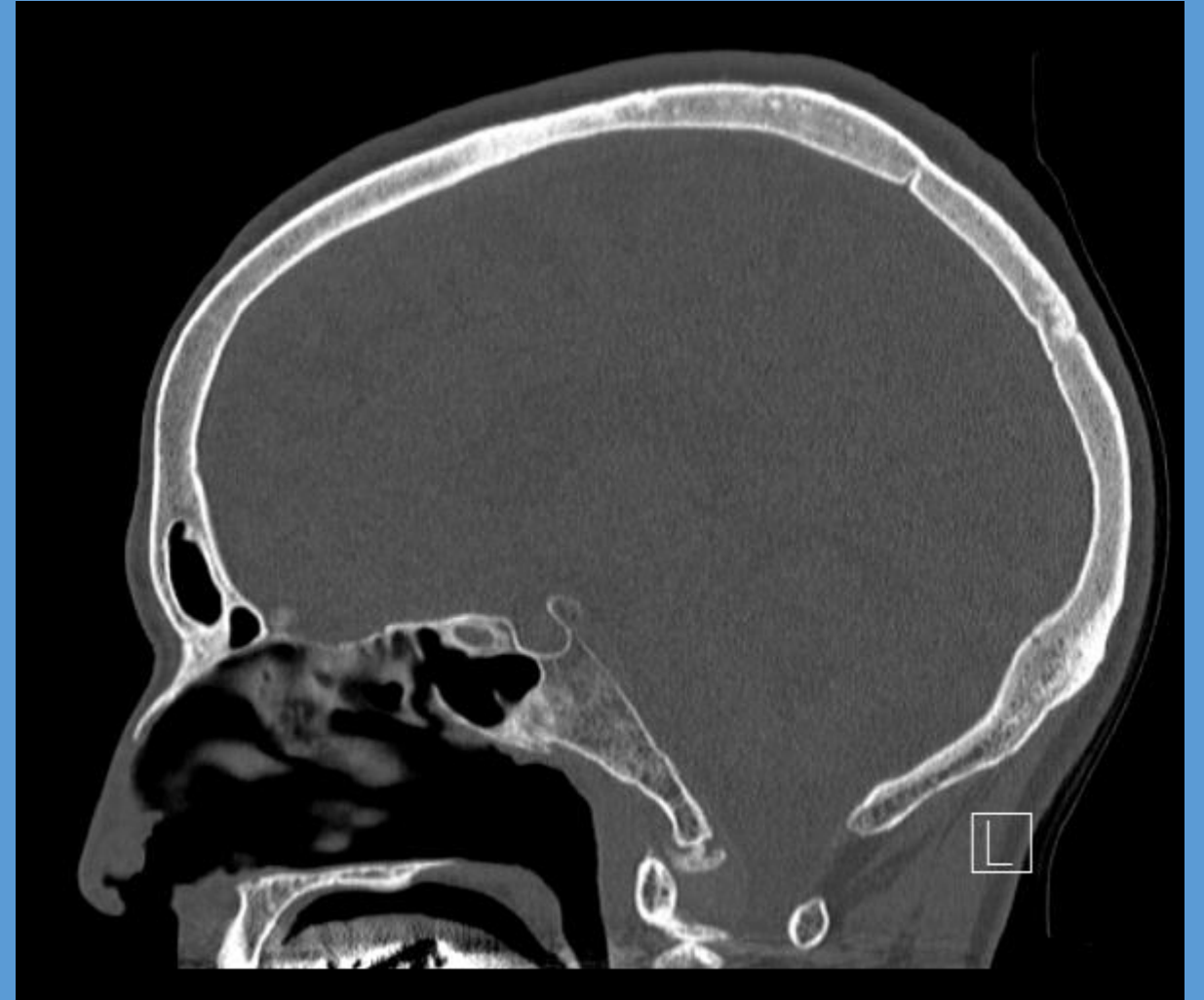

# Sinus Surgery (sphenoid)

Before



After



# FESS

- 1-2 hour surgery
- Done through the nose (ie no external incisions)
- Home same day
- No packing or bruising (almost never)
- Plastic splints to keep shape inside, removed 1-2 weeks following surgery
- Stuffy nose and hard to sleep are biggest complaints
- Nose hurts if you bump it
- Usually about a week off work, two weeks off strenuous activity

# FESS

- 80% “cure” rate – cannot surgically remove allergies or migraine headaches
- Allows ventilation which helps sinuses to be much more resilient to infection
- Equally important impact is open anatomy allows topical treatments

# FESS – new developments

- Computer assisted image guidance allows more complete and maybe safer surgery
- New steroid eluting stents available for slow topical delivery of steroids over an extended period
- Balloon sinuplasty – selectively dilate sinus openings to reset ventilation, limited longer term improvement
- Office procedure suite – for smaller procedures, avoids need for general anesthetic, quicker recovery, much less expensive

# Summary

- Sinusitis is extremely common
- **Odontogenic sinusitis** is very common amongst cases of sinusitis (40%)
- More suspicious if **unilateral maxillary sinusitis, malodorous drainage, localizing cheek or dental pain**
- Some require only ENT or only dental eval/tx, some require both
- Maximal medical therapy first, then consider sinus surgery
- **Modern sinus surgery is relatively easy**, quicker and less painful recovery, *without packing*

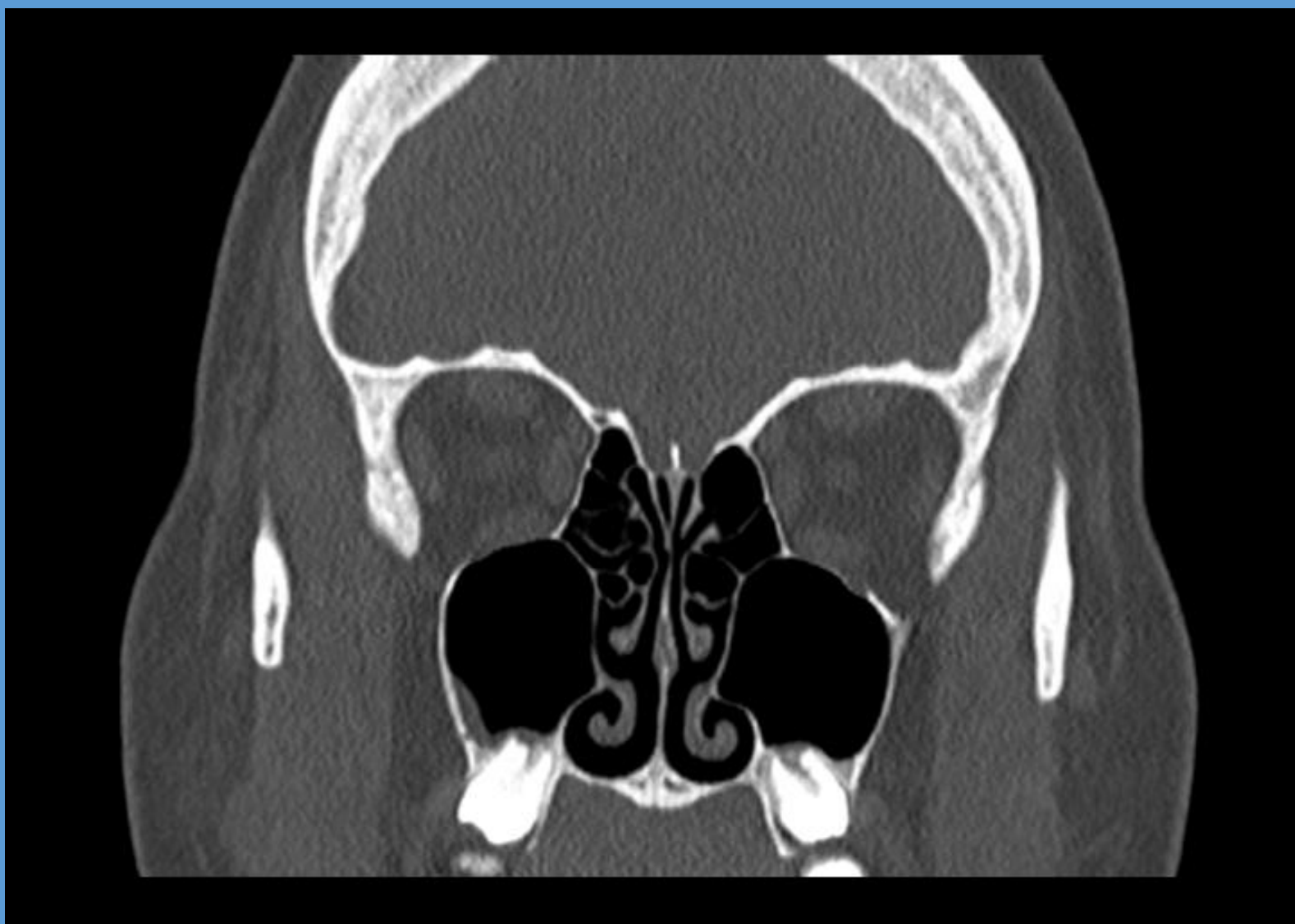

# Summary

*So....who should do what...and in what order?*

1. If has localizing symptoms and isolated CT findings over one tooth, then probably dental consideration first

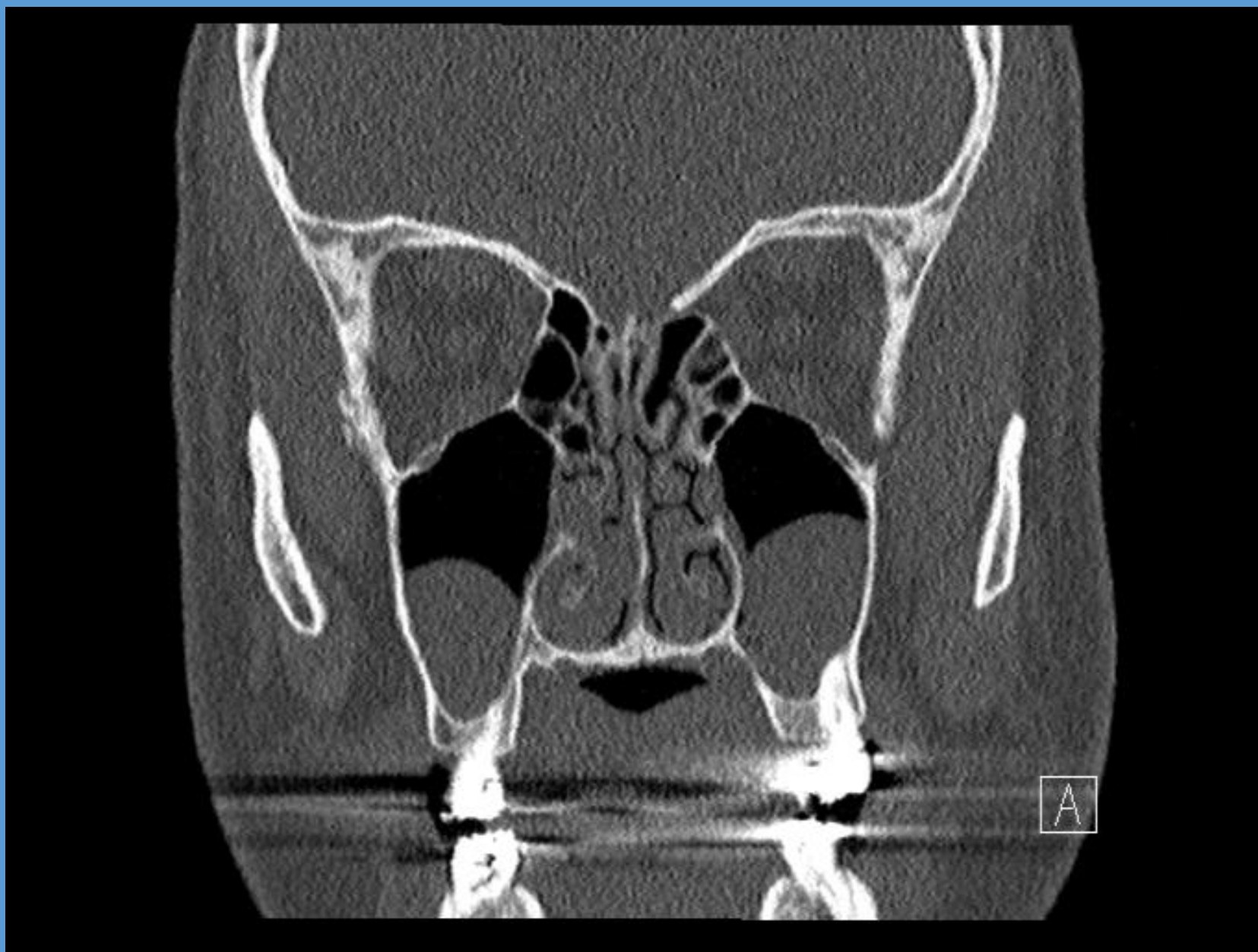



# Summary

*So....who should do what...and in what order?*

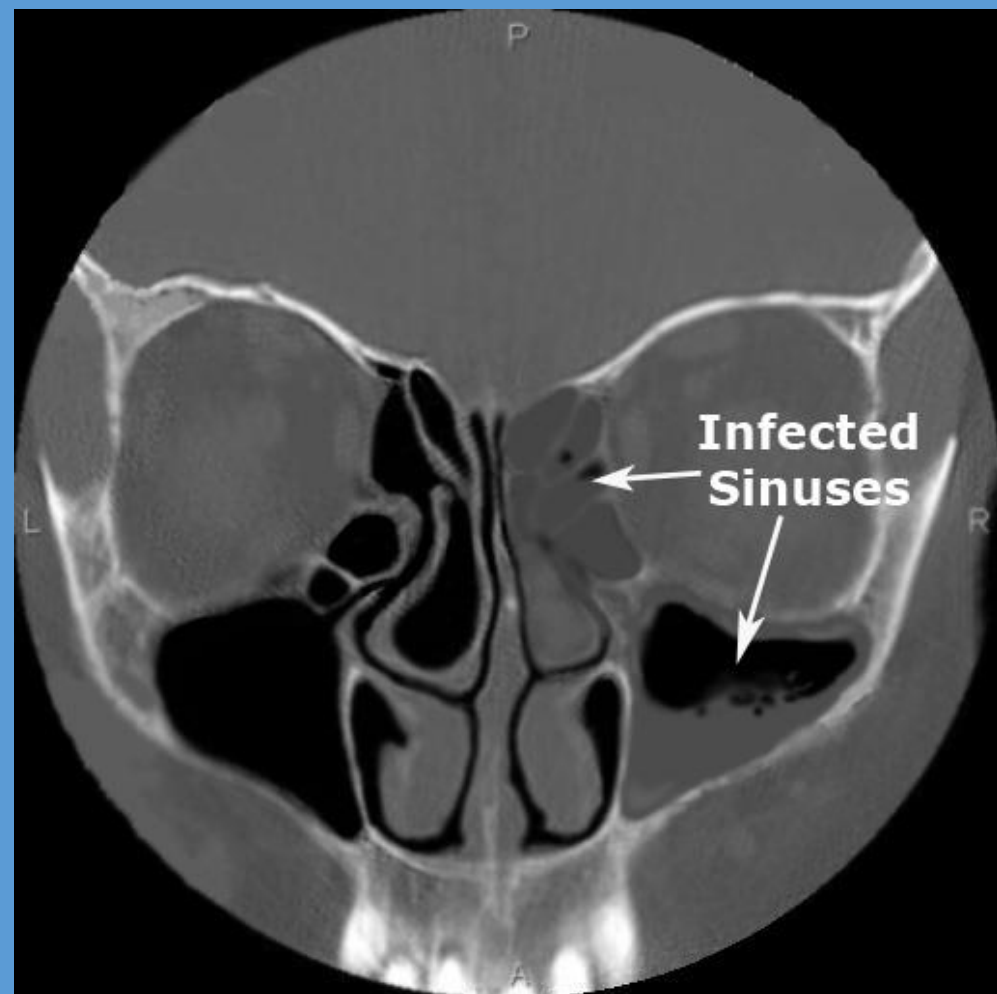
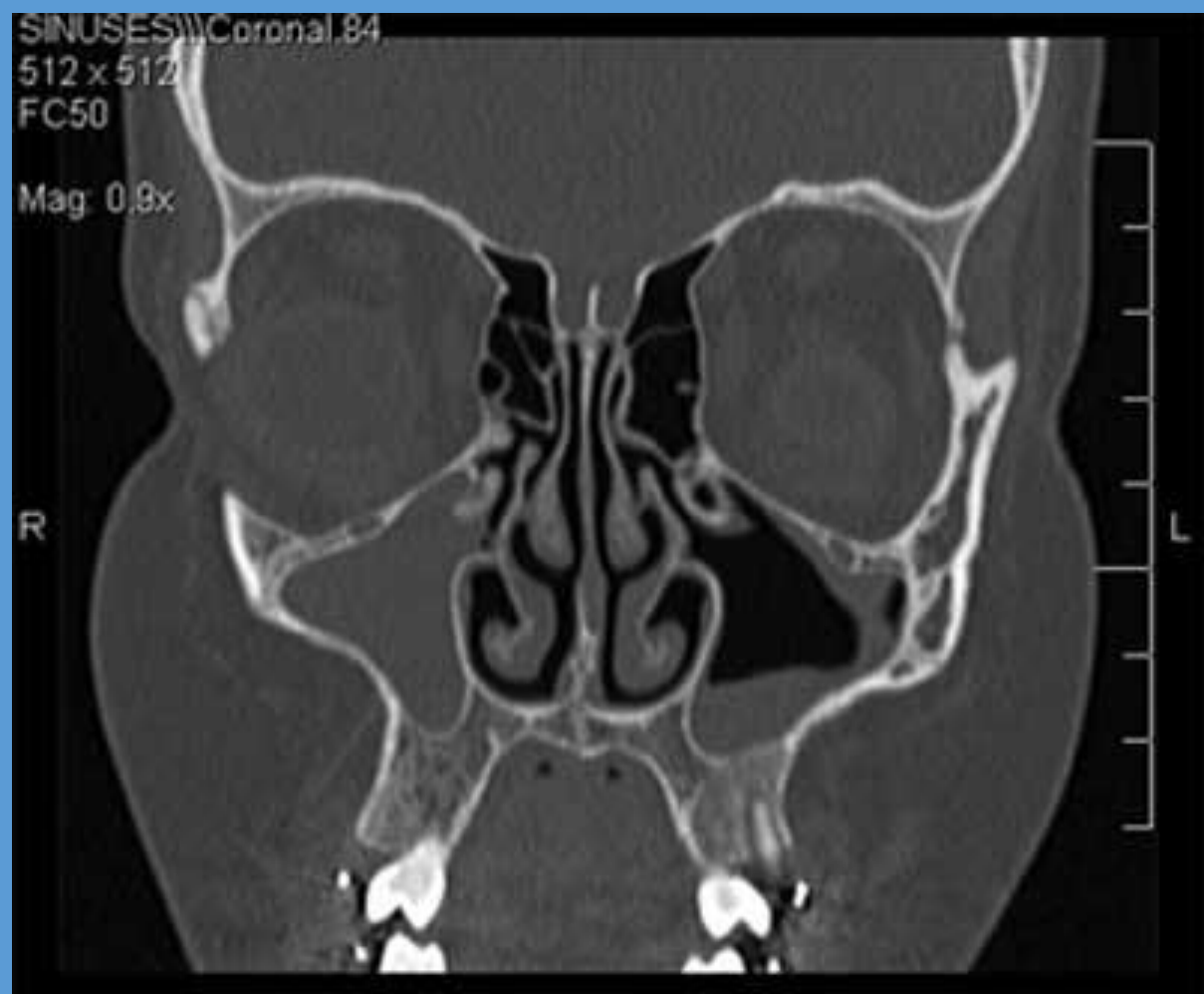
1. If has localizing symptoms and isolated CT findings over one tooth, then probably dental consideration first, ie unilateral maxillary sinus, pain, malodorous drainage
2. If has multitude of symptoms, including dental pain, then may need both. Referral and which to treat first directed by imaging and symptom severity.



# Summary

*So....who should do what...and in what order?*

1. If has localizing symptoms and isolated CT findings over one tooth, then probably dental consideration first, ie unilateral maxillary sinus, pain, malodorous drainage
2. If has multitude of symptoms, including dental pain, then may need both. Referral and which to treat first directed by imaging and symptom severity.
3. If pretty severe sinus symptoms, and imaging more concerning...ie complete sinus opacification, then probably ENT first.

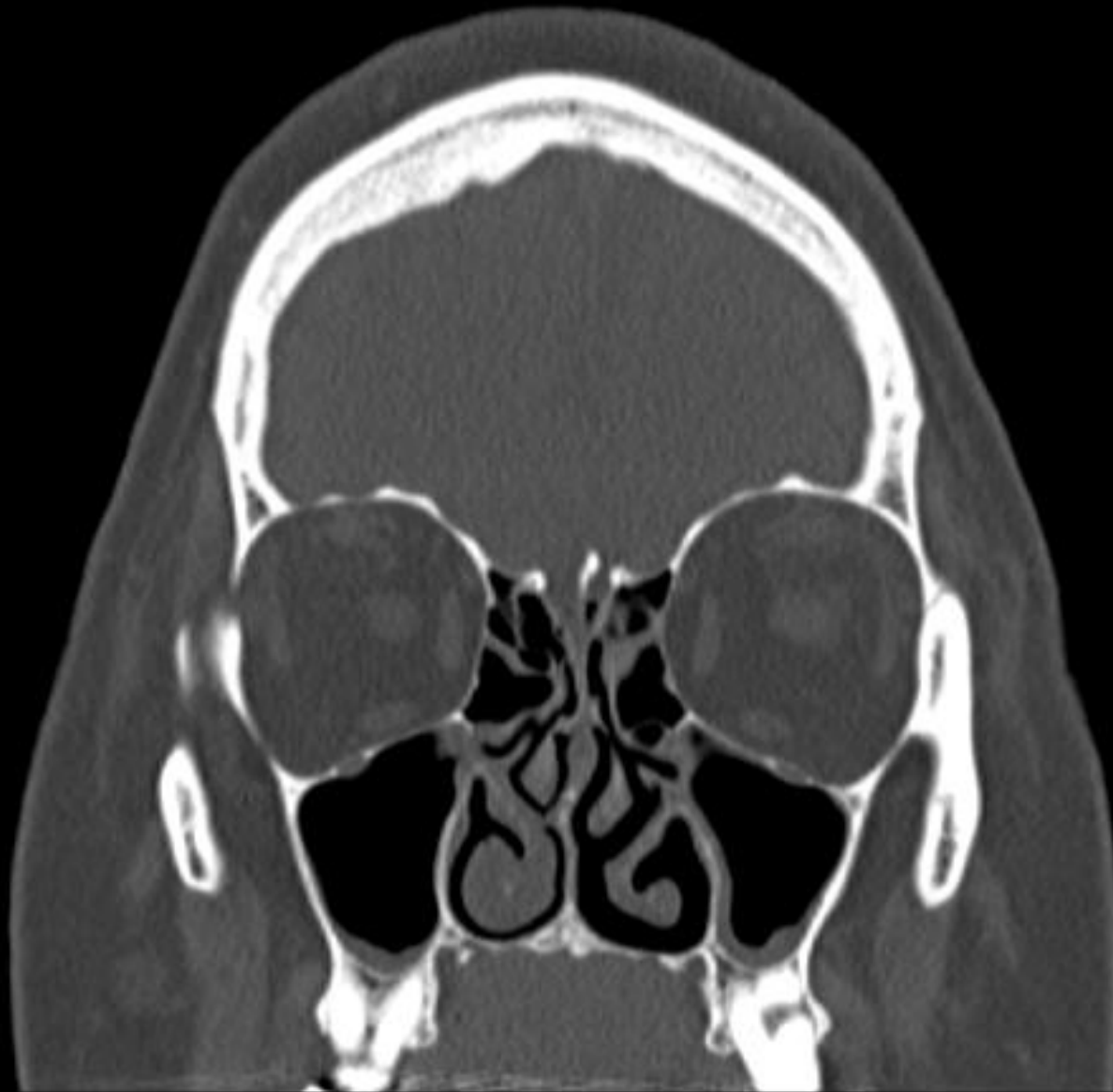


# Summary

*So....who should do what...and in what order?*

1. If has localizing symptoms and isolated CT findings over one tooth, then probably dental consideration first, ie unilateral maxillary sinus, pain, malodorous drainage
2. If has multitude of symptoms, including dental pain, then may need both. Referral and which to treat first directed by imaging and symptom severity.
3. If pretty severe sinus symptoms, and imaging more concerning...ie complete sinus opacification, then probably ENT first.
4. In many, initial treatment with either specialty may only partially alleviate symptoms, necessitating treatment by both.





# The Everett Clinic ENT Department



**Paul Abson, MD**  
General ENT, head and neck  
cancer, thyroid/parathyroid  
Everett



**Jeff Adams, MD**  
General ENT, thyroid/parathyroid,  
head and neck cancer  
Department chair  
Edmonds and Everett



**Natalie Higgins, MD**  
General ENT, facial plastics and  
reconstructive surgery  
Smokey Point



**Amy Williams, NP**  
General ENT, dysphagia,  
vertigo, tinnitus, ear cleaning  
Everett



**Lisa Mulligan, MD**  
General ENT, otology  
Everett



**Sal Taliencio, MD**  
General ENT, laryngology, head  
and neck cancer, thyroid  
Everett and Smokey Point



**Emily Coraci, PA-C**  
General ENT, dysphagia,  
vertigo, tinnitus, ear cleaning  
Smokey Point

# The Everett Clinic ENT Department

**Reception line – 425-339-5441**    Back lines: Smokey Point – 360-454-1929    Main Campus Everett – 425-259-1189    Edmonds - 425-412-1879

For urgent issues or any questions contact Jeff Adams: email – [jadams@everettclinic.com](mailto:jadams@everettclinic.com), office 425-339-1177, ext 2588

## Subspecialty services:

***Pediatric ENT*** – any diagnoses, any age. For routine peds surgery at our surgery center we can get **tubes done at 9 months old, adenoids at 1 year, and tonsils at 3 years. Can get tonsils done at 2 years at the hospital in rare case needed that early.**

***Nose and sinuses*** – simple to tertiary level care for nasal obstruction, **advanced sinus disease, polyps, sinonasal tumors...pediatric sinus surgery too**

***Thyroid and parathyroid*** – busy endocrine service with **fellowship trained surgeons, minimally invasive** surgery techniques

***Laryngology and voice*** – **fellowship trained** expertise for patients with difficult throat, voice and swallowing complaints

***Facial plastic surgery*** – **fellowship trained surgeon** for all cosmetic and reconstructive needs...botox, rhinoplasty, facelift, brow lift, blepharoplasty, skin cancer reconstruction

***Otology*** – subspecialty trained surgeon, **all ear needs**, ear drum reconstruction, cholesteatoma, ossiculoplasty, endoscopic ear surgery

***Head and neck cancer*** - **fellowship trained** surgeons for any tumors of the face, mouth or throat, neck masses

***Vertigo*** – advanced vestibular and audiologic testing, treatment

# Other resources...

- **TEC Allergy - 425-339-5412**
- **TEC Pulmonary and Sleep Medicine - 425-339-5410**
- **TEC Neurology - 425-339-5431**